

ORIGINAL PAPER

Endoscopic Management of Foreign Bodies in the Airways and Esophagus of Children

Goswami Jayanta Kr¹

Received on September 15, 2015; editorial approval on December 8, 2015

ABSTRACT

Foreign body in the esophagus and airway in children is an important cause of morbidity and mortality. The aim of this study is to summarize the experience of diagnosis and treatment of tracheobronchial and esophageal foreign bodies in children. The medical records of 15 such cases admitted in Pediatric Surgery Department, Gauhati Medical College, Guwahati from June 2008 to May 2015 were analyzed. Amongst these 15 children, 9 were with airway and 6 with esophageal foreign bodies. Out of these 12 were boys (80%) and 3 girls (20%). Direct laryngoscopy, 3 by rigid esophagoscopy and 1 by flexible endoscopy removed two esophageal foreign bodies. All the 9 airway foreign bodies were removed by rigid bronchoscopy with the help of optical forceps. Seven of these were in the right bronchus and one each in the left bronchus and carina. Two patients needed ventilation after the procedure. The most common foreign body in the esophagus was coin and that of airway was peanut. There were variable period morbidities but all of these fifteen patients went home without any residual effect.

Timely diagnosis and management of foreign bodies in children is utmost important and this can reduce the complications and mortality related to it.

Keywords: Foreign body bronchus, foreign body esophagus, foreign body in children

Address for correspondence and reprint:

¹Associate Professor

Dept. of Pediatric Surgery, Gauhati Medical College, Guwahati-32

Mobile: +91 9864063815

Email: drjayanta@hotmail.com

INTRODUCTION

The child's instinct to explore the surrounding and their experimentation with the various objects are the main causes of foreign body (FB) lodgment in the esophagus and in the airway in them. Accident often contributes to it. Unless managed urgently most of these cases, especially those with airway FB may turn serious and even may cause death. Though nonsurgical endoscopic removal of these FBs is an established procedure, some patients may require open procedure as well. Here, we are presenting our seven-year experience of management of foreign bodies from the pharynx, esophagus and tracheobronchial tree with the help of endoscopes.

MATERIAL AND METHODS

This is a retrospective analysis of the patients treated in a tertiary centre. The duration was seven years from June, 2008 to May, 2015. Age and sex incidence, time of presentation, presenting signs and symptoms, site of retrieval of FB, instrument and accessories used and post procedure outcome were recorded. All the cases came with the plain x-ray of the chest. General anesthesia was employed in all the cases. Rigid ventilating bronchoscopes (Richard Wolf) of appropriate size (2.5-6mm), with optical forceps and rod lens telescopes were used for FB in the airways. Direct laryngoscopy and Magill's forceps removed two pharyngeal FBs. For one esophageal FB 9 mm Fuginon fiber optic flexible esophago-gastroscope with basket was used. In two cases of coin (**Figure 1**) and one of headless open safety pin (**Figure 2**) in the esophagus rigid esophagoscope and Maryland forceps meant for laparoscopy was used.

One FB could not be removed because of technical difficulty and was managed in other department by thoracotomy and bronchotomy. This case is excluded from our series.

All the cases were admitted for variable period and were followed up in the outpatient department after their discharge.

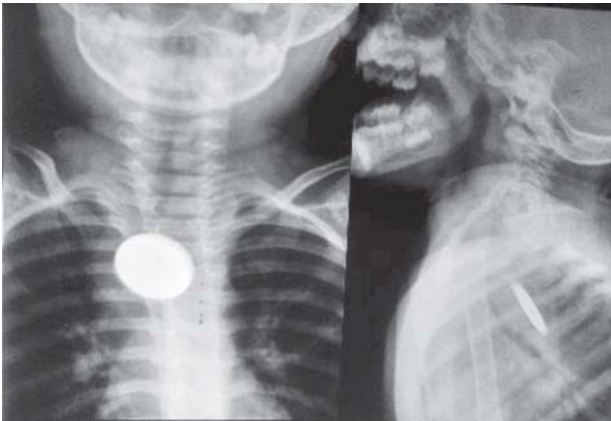


Figure 1 Coin in the upper esophagus

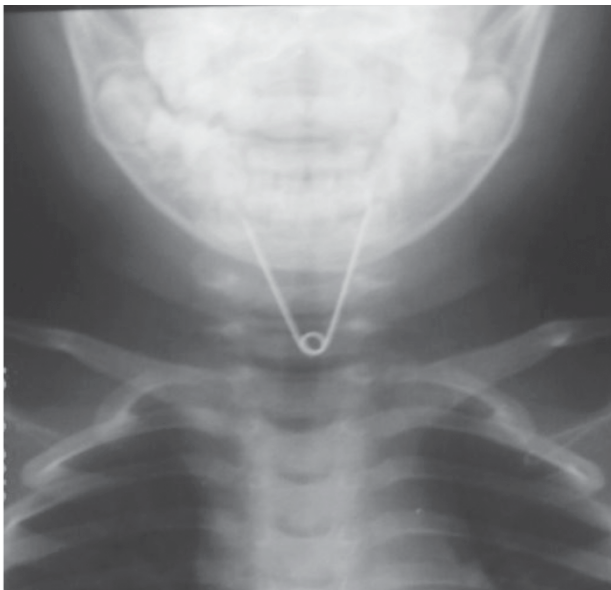

Figure 2 Open safety pin in esophagus

RESULTS AND OBSERVATIONS

SITE OF LODGMENT

Site of lodgment of FB was as follows (Figure 3):

Out of the fifteen FBs six were lodged in the esophagus.

Out of these six, three viz. two coins and one headless safety pin were in the upper esophagus and rest three viz. two coins and one locket was found in the lower esophagus.

In the airway seven foreign bodies were in the right bronchus (77.78%), one each in the left bronchus (11.11%) and carina (11.11%).

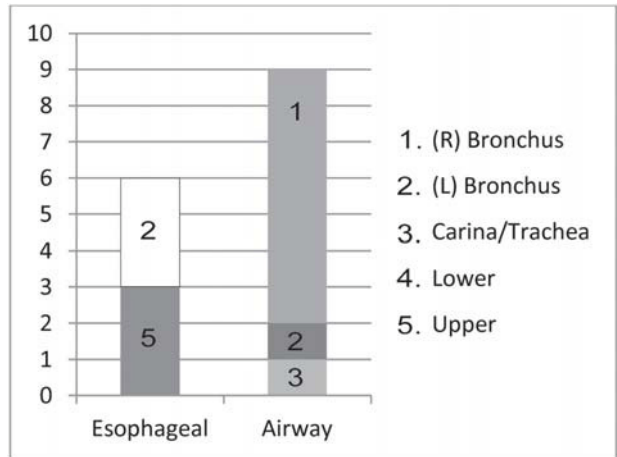


Figure 3 Bar chart depicting site of lodgment of foreign bodies

AGE DISTRIBUTION

The age ranged from 6 months to 7 years. Median age was 3 years. Highest number of cases recorded from 2 to 4 years of age (Table 1).

Table 1 Age wise distribution of cases

Age	FB in esophagus	FB in airway	Total	Percentage
6m to 1 yr	0	1	1	6.67%
1yr+ to 2 yr	0	3	3	20%
2yr+ to 3 yr	2	2	4	26.67%
3yr+ to 4 Yr	3	1	4	26.67%
4yr+ to 7 yr	1	2	3	20%
Total	6	9	15	100%

SEX DISTRIBUTION

As shown in Table 2 male child were more in number. In esophageal FB except a case with coin, all were male child.

Table 2 Sex wise distribution of cases

Sex	No of Patients	Percentage
Male	12	80%
Female	3	20%

CLINICAL PRESENTATION

All the case except three presented as acute emergency. A patient with a broken pin of a mobile charger presented after one month and LED bulb after 3 months. Both the FBs were in the right main bronchus. A patient with coin in the esophagus came after nine days of occurrence.

All the patients with airway FBs had respiratory difficulties and those of esophageal FBs had salivation and difficulty in swallowing. A patient with whistle in the right bronchus presented with whistling sound on deep breathing or in crying. One patient with severe respiratory distress and bradycardia was taken directly to operation theater and was managed as dire emergency. The presenting features are shown in **Table 3**.

Table 3 Clinical presentations

History, symptoms and signs	No. of patients	Esophageal (n=6)	Percentage	Airway (n=9)	Percentage	Total percentage
Positive history	13	6	100%	7	77.78%	86.67%
Salivation	3	3	50%	0	0%	20%
Difficulty in swallowing	7	6	100%	1	11.11%	46.67%
Difficulty in breathing	8	0	0%	8	88.89%	53.33%
Wheeze	7	0	0%	7	77.78%	46.67%
Whistling sound	1	0	0%	1	11.11%	6.67%

INVESTIGATIONS

All the patients presented with plain x-rays of the chest. Metallic FBs were obvious in the film. The glass part of LED bulb FB was radiolucent. But inner metallic part could be seen clearly. Out of the six patients with organic FBs in the airway one had collapse of right lung and pneumothorax. In two other patients x-ray hyperinflation of the affected lung was found. But none of these cases showed FBs.

This case with LED bulb and the charger pin came with CT scans at their presentation.

REMOVAL

Two coins lodged in upper esophagus were removed by direct laryngoscopy and with Magill's forceps. Two coins in the mid esophagus needed rigid esophagoscopy and removal with rigid forceps. A locket in the mid esophagus was removed by flexible esophago-gastroscope with a wire basket used through its instrument channel. In a patient where FB was a broken open safety pin needed special maneuver. Holding the spring with the forceps the pin was rotated first to 180°, and then it was pulled partially inside the rigid scope. Lastly scope and FB was removed together (**Figure 4**).

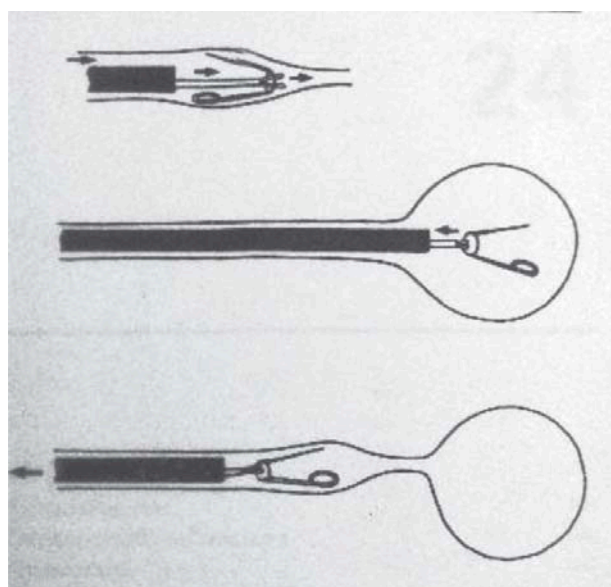


Figure 4 Schematic diagram of method of removal of open safety pin

Airway FBs were removed by rigid ventilating bronchoscope aided by optical foreign body forceps. One FB (LED bulb) during its removal dislodged from the forceps after passing the larynx and was retrieved from the pharynx by a Magill's forceps.

FOREIGN BODIES

Various FBs encountered and their sites of lodgment are tabled in **Table 4**. In the esophageal FB coin and in the airway peanut were commonly encountered. **Figure 5** shows some of the FBs removed.

Table 4 Foreign bodies removed

Foreign body	Site	Number
Coin	Esophagus	4
Locket (Cross)	Esophagus	1
Open safety pin	Esophagus	1
LED bulb	R-Bronchus	1
Broken Charger pin	R-Bronchus	1
Pea nut	R-Bronchus	3
Gram seed	L-Bronchus	1
Whistle	R-Bronchus	1
Chicken bone	R- Bronchus	1
Tamarind seed	Carina	1

**Figure 5** Some of the foreign bodies removed

RECOVERY AND HOSPITAL STAY

Two patients with upper esophageal FBs were allowed feeding after few hours of procedure and were discharged on the same day. Others were observed till next morning and feeding was started thereafter.

Seven out of nine airway FBs required post procedure oxygen supplementation by hood or by mask for few hours. Feeding was started in these cases gradually once their respiratory distress settled down. All these patients were discharged within 36 hours.

Two patients with airway FB required ventilation. One with peanut developed a right sided pneumothorax and surgical emphysema and was managed by insertion of a water seal intercostals drain. This patient was ventilated for 48 hours. Surgical emphysema disappeared spontaneously gradually. Patient was discharged on 6th postoperative day. Other patient with gram seed required 24 hours ventilation and was discharged after 4 days.

DISCUSSION

Open safety pin in pharynx and esophagus had been reported by several authors.^{1,2,3} In most of the cases these were removed endoscopically. Passey JC et al.³ reported a case of open safety pin in the esophagus, which caused perforation of common carotid artery. In our case of safety pin the head was missing and both the arms had sharp ends. In our literature search we have not found any such case.

Coin is the commonly encountered FB in the esophagus. In most of the centers it is removed with endoscopes. In early cases the procedure can be performed safely.^{4,5} Foley's balloon catheter with radiologic guidance is used in some centers where endoscopes are not available.⁶

In United States out of all accident related deaths in children below 4 years of age, 5% are due to FB aspiration.⁷

Toddler and young children because of their insufficient dentition often inhale the partially chewed foods.⁸ Gulati SP et al⁹ opined that pea nut is the commonest tracheobronchial FB encountered in India. In our series also amongst the airway FBs peanut was in the top of the list. Dyspnoea and bronchial reation is common in FB of vegetable origin.¹⁰ In the present series also one patient with peanut presented with severe respiratory distress. Other patients with vegetable FB also had moderate respiratory distresses.

In most of the series male cases outnumbered the female.^{11,12} In our series 12 patients(80%) were male and 3 (20%) were female.

In airway FB right bronchus was the commonest site in all the series. Fraga et al¹⁰ had 7 in right and 4 in left bronchus. While in the series of Tariq P¹³ right and left ratio was 1.4:1. Gang W et al¹⁴ in a mega series of 953 cases found 98 FB in the trachea or on both sides, 506 in the right bronchus and 349 in the left bronchus. In our series 5 were in the right and 1 was in the left bronchus. One FB was in the carina region.

According to Evans JNG¹⁵ the wider and more downward direction of right bronchus is the cause of predominance of right side.

CONCLUSION

Airway foreign body is often life threatening condition. Its removal requires skilled person and tertiary centre care. On the other hand smooth esophageal foreign bodies can be removed easily in the peripheral hospitals, if the technique is learnt properly.

Conflict of interest: None declared.

Ethical clearance: Taken.

Source of funding: None declared.

Declarations: (1) The article is original with the author and does not infringe any copyright or violate any other right of any third parties; (2) The article has not been published (whole or in part) elsewhere, and is not being considered for publication elsewhere in any form, except as provided herein; (3) Author has reviewed the final version of the above manuscript and approved it for publication.

REFERENCES

1. Kalayci A, Tander B, Kocak S, Rizalar R, Bernay F. Removal of open safety pins in infants by flexible endoscopy is effective and safe. *J Laparoendosc Adv Surg Tech A*. 2007 Apr;17(2):242-5. PMID: 17484658
2. Sarihan H, Kaklikkaya I, Ozcan F. Pediatric safety pin ingestion. *J Cardiovasc Surg (Torino)*. 1998 Aug;39(4):515-8. PMID: 9788804
3. Passey JC, Meher R, Agarwal S, Gupta B. Unusual complication of ingestion of a foreign body. *J Laryngol Otol*. 2003 Jul;117(7):566-567. PMID: 12901816
4. Tander B, Yazici M, Rizalar R, Arıturk E, Ayyıldız SH, Bernay F. Coin ingestion in children: which size is more risky? *J Laparoendosc Adv Surg Tech A*. 2009 Apr;19(2):241-3. PMID: 19215216
5. Pokharel R, Adhikari P, Bhusal CL, Guragain RP. Oesophageal foreign bodies in children. *JNMA J Nepal Med Assoc*. 2008 Oct-Dec;47(172):186-8. PubMed: 19079391
6. Bowa K, Bvulani B, Mukonge L. The use of Foley's catheter in the removal of a coin in the oesophagus. *Trop Doct*. 2009 Apr;39(2):97-8. PMID: 1929929
7. Rovin JD, Rodgers BM. Pediatric foreign body aspiration. *Pediatr Rev*. 2000 Mar;21(3):86-90. PubMed PMID: 10702322
8. Hayes NM, Chidekel A. Pediatric choking. *Del Med J*. 2004 Sep;76(9):335-40. PMID:15510972
9. Gulati SP, Kumar A, Sachdeva A, Arora S. Indian J Med Sci. Groundnut as the commonest foreign body of tracheobronchial tree in winter in Northern India. An analysis of fourteen cases. 2003 Jun;57(6):244-8. PMID:14510341
10. Fraga Ade M, Reis MC, Zambon MP, Toro IC, Ribeiro JD, Baracat EC. Foreign body aspiration in children: clinical aspects, radiological aspects and bronchoscopic treatment. *J Bras Pneumol*. 2008 Feb;34(2):74-82. PMID: 18345450
11. Kaur K, Sonkhya N, Bapna AS. Foreign bodies in the tracheobronchial tree: A prospective study of fifty cases. *Indian J Otolaryngol Head Neck Surg*. 2002 Jan;54(1):30-4. PMID: 23119848
12. Paksu S, Paksu MS, Kilic M, Guner SN, Baysal K, Sancak R, Ozturk F. Foreign body aspiration in childhood: evaluation of diagnostic parameters. *Pediatr Emerg Care*. 2012 Mar;28(3):259-64. PMID: 22344214
13. Tariq P. Foreign body aspiration in children—a persistent problem. *J Pak Med Assoc*. 1999 Feb;49(2):33-6. PMID: 10513434
14. Gang W, Zhengxia P, Hongbo L, Yonggang L, Jiangtao D, Shengde W, Chun W. Diagnosis and treatment of tracheobronchial foreign bodies in 1024 children. *J Pediatr Surg*. 2012 Nov;47(11):2004-10. PMID: 23163990
15. Evans JNG. Foreign bodies in the larynx and trachea. In: Kerr AG, editor. *Scott Brown's Otolaryngology*, 5th edn. London: Butterworth; 1987. P. 288-91.