



International Journal of Health Research and Medico-Legal Practice

Copyright ©Roy DK, Kalita D, Bhuyan R, Basu A, Killing S. This is an open-access article distributed under the Creative Commons Attribution License permits unrestricted use, distribution, and reproduction in any medium, provided the original work is properly cited



RESEARCH PAPER

A comparative study between ultrasound and the modified Alvarado score for the diagnosis of acute appendicitis

Article ID: 570

Roy DK¹, Kalita D², Bhuyan R³, Basu A⁴, Killing S⁵

Address for correspondence:

¹Professor and head

Mobile: +919864064127

Email: drdeepkrroy@gmail.com

²Post-graduate Trainee (Corresponding author)

Mobile: +919864064127

Email: drdarpanak@gmail.com

ORCID ID:

0000-0003-0721-4370

^{3,4}Associate Professor

⁵Assistant Professor

Deptt. of Radiodiagnosis

Jorbat Medical College and Hospital, Jail Road, Jorbat, Assam-01

Article received: 07-01-2023

Received (revised): 17-04-2023

Editorial approval: 30-05-2023

Checked for plagiarism: Yes

Peer-reviewed article: Yes

Editor who approved:

Dr DS Yadav MSc, PhD

ABSTRACT

Background and aims: Accurate diagnosis of acute appendicitis is challenging despite advances in modern radiodiagnosis and laboratory investigations. The Alvarado score is a numerical scoring system for the signs and symptoms associated with acute appendicitis. This scoring system was modified to exclude neutrophils as a parameter. Ultrasonography (USG) is an essential and routine diagnostic tool for diagnosing acute appendicitis. The study aims to determine the diagnostic accuracy of ultrasonography compared to the modified Alvarado score for the diagnosis of acute appendicitis.

Methods: A prospective observational study of 43 patients who underwent appendectomy for suspected acute appendicitis at Jorbat Medical College and Hospital was done by collecting the patients' clinical, radiological, and ultrasonographic data. Any patient who presented with suspected acute appendicitis at the Jorbat Medical College and Hospital was included in the study. The exclusion criteria were patients with a different diagnosis at the end of the evaluation and patients who voluntarily opted out of the study. These patients were evaluated by modified Alvarado score and ultrasonography, and the findings correlated with histopathological reports.

Results: Eighteen patients are males, and twenty-five patients are females. Most patients belong to the rural population (58.1%). Out of the total study population, 3 cases had no appendicitis by modified Alvarado and USG, 10 cases showed appendicitis on modified Alvarado score, 14 cases showed appendicitis on USG and 16 cases on both. The results are not statistically significant ($p > 0.05$).

Conclusion: Combining ultrasonography and the modified Alvarado score can improve diagnostic accuracy for acute appendicitis, but ultrasonography alone is insufficient for diagnosis.

Keywords: Neutrophil; diagnostic; numerical; clinical; radiological; histopathological.

Cite this article: Roy DK, Kalita D, Bhuyan R, Basu A, Killing S. A comparative study between ultrasound and the modified Alvarado score for diagnosing acute appendicitis. *Int J Health Res Medico Leg Prae* 2023 Jan-Jun;9(1):x-y. Doi: 10.31741/ijhrmlp.v9.i1.2023.7

INTRODUCTION

Acute appendicitis is one of the most common emergencies of the acute abdomen worldwide, which is usually classified into simple (non-perforated) and complex (gangrenous or perforated) appendicitis.¹ Appendicitis is most common in the second decade of life, between 10 to

20 years. But it can occur at any age. Male to female ratio is 1.4:1, with an overall lifetime risk is 8.6% for males and 6.7% for females in the United States. Faecoliths, foreign bodies, malignancy, and lymphoid hyperplasia during an infection are possible etiologies. There is no known genetic cause of acute appendicitis. The possible pathophysiology is a luminal

obstruction that blocks the escape of mucosal secretions, leading to increased pressure which causes engorgement and stasis. This causes necrosis and, eventually, appendicular perforation.² Acute appendicitis is the most common non-obstetric cause of surgical emergencies during pregnancy. Many complications include wound infection, intestinal obstruction, respiratory complications, preterm labour, and fetal mortality. The estimated incidence of acute appendicitis in pregnancy varies from 1.8 to 41 per 10,000 pregnancies, with the highest risk during the third trimester. The risk of negative appendicectomy is more significant in pregnant than in non-pregnant women due to diagnostic difficulty. Also, the highest and lowest negative appendectomy rates were encountered in the second and third trimesters, respectively.³ Pathologically, it can be classified as intraluminal, acute mucosal, acute mucosal and submucosal, suppurative (phlegmonous), and gangrenous appendicitis.⁴

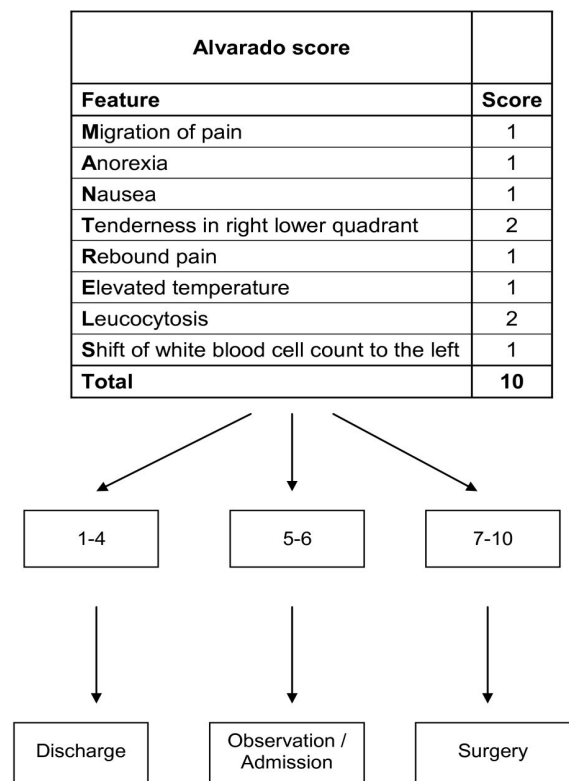
Diagnosing acute appendicitis can be done by clinical combined with pathological and radiological methods. Clinically, there is pain in the right iliac fossa with low-grade fever, nausea, and vomiting. An alternative sequela is that the appendix becomes surrounded by a mass of omentum or adjacent viscera which walls off the inflammatory process and prevents inflammation from spreading to the abdominal cavity.² 1986 Alvarado formulated a 10-point clinical scoring system for patients with suspected acute appendicitis (**Figure 1**). This is known by the acronym MANTRELS and is based on symptoms, signs, and laboratory parameters.⁵ It is later developed into the Modified Alvarado Scoring System by omitting the left shift of leukocytosis from the Alvarado Score.⁶

The main ultrasonographic signs for the diagnosis of acute appendicitis are an appendiceal diameter of more than 6 mm, increased appendiceal wall thickness greater than 3 mm, presence of an appendicolith, presence of an allantoic mass, loss of rounded appendiceal appearance in transverse view, loss of peristalsis and non-compressible appendix during pressure application with the transducer. Other signs which contribute towards acute appendicitis are the presence of free fluid between the intestinal helices, increased vascularity, and hyperechoic mesenteric fat.⁷

Appendicectomy for acute appendicitis remains the most common urgent/emergent surgical procedure. But,

recent evidence show a 3.5-fold excess mortality after surgical intervention for non-perforated appendicitis and a 6.5-fold excess mortality in perforated ones. The mortality risk increases to 9.1fold after negative appendicectomy following non-specific abdominal pain.⁸ Current evidence shows the changes in clinical practice towards the non-operative management of several cases of acute appendicitis, either non-complicated or complicated. It is found that mesenchymal stem cells are present in the vermiform appendix, which can differentiate into osteoblasts, lip blasts, and myoblasts and acts like a reservoir for stem cells capable of bowel repair.⁹

Hence, this study is done to determine the diagnostic accuracy of ultrasonography compared to the modified Alvarado score for diagnosing acute appendicitis.



Predicted number of patients with appendicitis:

- Alvarado score 1-4 - 30%
- Alvarado score 5-6 - 66%
- Alvarado score 7-10 - 93%

Figure 1 The Alvarado Score⁶

MATERIALS AND METHODS

A prospective observational study was done at the Department of Radiodiagnosis, Jorhat Medical College and Hospital, from November 2021 to October 2022. The sample size was 43 patients. The inclusion criteria were any patient who presented with suspected acute appendicitis at the Jorhat Medical College and Hospital. The exclusion criteria were patients with a different diagnosis at the end of the evaluation and patients who voluntarily opted out of the study.

The study collected all the patients' clinical, radiological, and ultrasonographic data. These patients were evaluated by modified Alvarado score and ultrasonography, and the findings correlated with histopathological reports. The study was done following written and informed consent from the patients. Ultrasonography was done using linear transducer L3-12A of Samsung RS80A ultrasound machine, which was available in our department. Ultrasonography was done in a supine position on a table with proper abdominal exposure starting from the level of the nipple to the suprapubic area with a little bit of manipulation of the probe to scan the pelvic organ. A water-based gel is used to secure contact of the transducer with the body and block the air pockets between the transducer and the skin, which can block the sound waves. All the abdomen areas were scanned to establish the diagnosis and rule out any other causes of acute abdomen. The ultrasonographic images of a normal appendix (**Figure 2**) and an acute, inflamed appendix (**Figures 3 and 4**) are shown below.

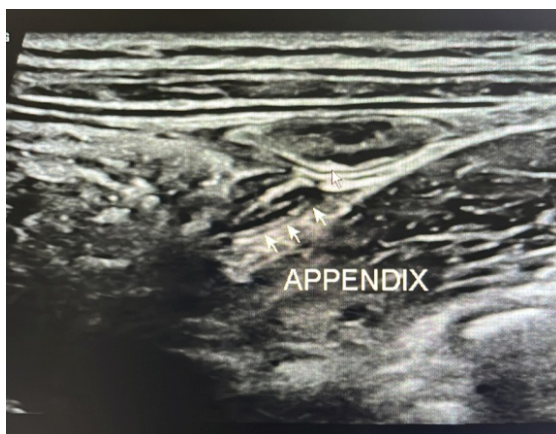

Figure 2 Ultrasonographic features of a normal appendix (arrow)

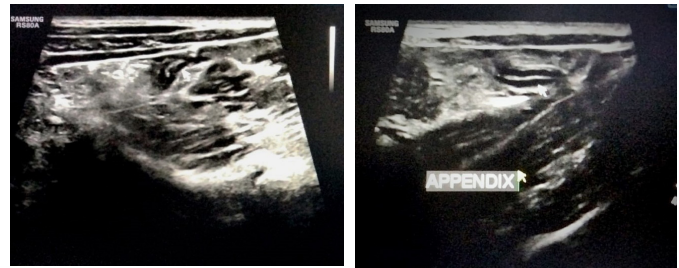

Figure 3 (a,b) USG images of an Inflamed appendix (arrow) with an intraluminal diameter of 6.7mm and echogenic wall

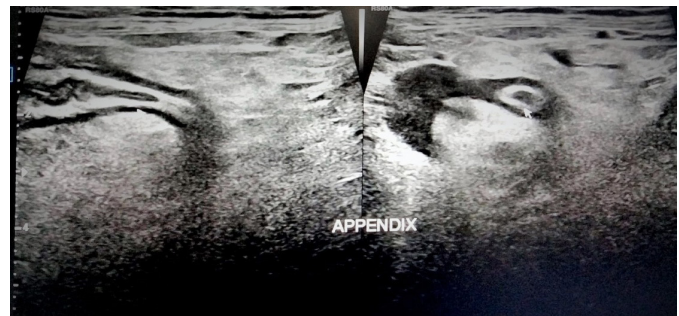


Figure 4 USG images of an inflamed appendix (single arrow) with an intraluminal diameter of 7.4mm, echogenic wall and surrounding hypoechoic minimal peri-appendiceal collection (double arrow)

A proforma and a master chart were maintained for analysis. Statistical analysis was done, and Mann Whitney U Test was applied to analyse the data.

RESULTS

Eighteen patients are males, and twenty-five patients are females. Most of the patients belong to the rural population (58.1%) and are between 20-40 years of age (68.1%). The Sensitivity of ultrasonography alone in detecting acute appendicitis is 69.77%, and that by Alvarado's score alone is 60.46%. The combined sensitivity is 37.21%. The results were not significant as the p -value > 0.05 .

Table 1 Sensitivity of ultrasonography, Alvarado score & combination in detecting acute appendicitis

		Alvarado		Total	p-value
		No	Yes		
USG	No	3	10	13	0.187
	Yes	14	16	30	
Total		17	26	43	

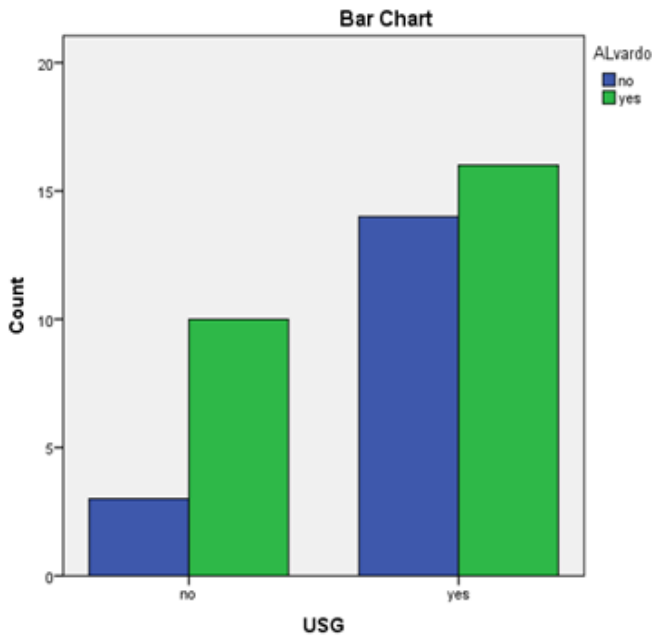


Figure 5 Sensitivity of ultrasonography, Alvarado score and combination in detecting acute appendicitis

DISCUSSION

The study by Richard Nshuti *et al.* showed that the mean age of presentation of acute appendicitis is 26 years (SD = 12 years) with a male-to-female ratio of 1.6:1. Sensitivity of the ultrasound to detect acute appendicitis is 60%.⁹ Another study by S. Barlas *et al.* concluded that appendicitis was most common among males between 10 to 19 years of age.¹⁰ The study conducted by Yashmine Lounis *et al.* shows that acute appendicitis is rare in children under six years of age and has a high risk of morbidity due to delays in diagnosis due to non-specific symptoms.¹¹ In our study, most of the population is between 20 to 30 years of age.

A recent study conducted by C Federico *et al.*¹² showed that ultrasound alone resulted in 87% correct diagnosis of acute appendicitis. With the Alvarado score alone, a correct diagnosis was made 88% of the time. There were 45 true positives and no false positive cases when both modalities were positive for appendicitis.¹² Another study by Mohamed Zouari *et al.* concluded that when the Alvarado score and ultrasound are taken together, it improves the predictive value of diagnosing acute appendicitis, especially in the paediatric population. The study suggested pre-operative ultrasonography in patients with moderate or low Alvarado scores.¹³ Another study showed that ultrasonography was better for diagnosing positive findings for acute appendicitis, while CT was better for exclusion. A low negative appendectomy rate can be achieved by combining radiological examination with the results from the clinical examination and laboratory parameters.¹⁴ Our study concluded that the combined Sensitivity of ultrasonography and modified Alvarado Score is better than each modality individually.

The study done by Hemant Nautiya *et al.* also showed that the use of modified Alvarado score and high-frequency USG together not only reduces negative appendectomy rate but also reduces morbidity and postoperative complications.¹⁵

CONCLUSION

Ultrasonography helps diagnose acute appendicitis and can be included as a part of the modified Alvarado score as a predictor of Acute Appendicitis. This will further enhance diagnostic accuracy and reduce negative appendicectomies' rate. This will also reduce a patient's exposure towards unnecessary morbidities and mortalities associated with a surgical procedure. Still, these parameters cannot be used independently to accurately diagnose acute appendicitis.

REFERENCES

1. Bhangu A, Søreide K, Di Saverio S, Assarsson JH, Drake FT. Acute appendicitis: modern understanding of pathogenesis, diagnosis, and management. *The Lancet* 2015 Sep 26;386(10000):1278-87.
2. Kasabe PS, Relekar MR. Comparison of Alvarado score and ultrasonography in the diagnosis of acute appendicitis. *International Journal of Surgery* 2020;4(2):109-13.
3. Zingone F, Sultan AA, Humes DJ, West J. Risk of acute appendicitis in and around pregnancy: a population-based cohort study from England. *Annals of surgery* 2015 Feb 1;261(2):332-7.

4. Carr, NJ. The pathology of acute appendicitis. *Annals of diagnostic pathology* 2000 Feb 1;4(1):46-58.
5. Ohle R, O'Reilly F, O'Brien KK, Fahey T, Dimitrov BD. The Alvarado score for predicting acute appendicitis: a systematic review. *BMC Medicine* 2011 Dec;9:1-3.
6. Nasiri S, Mohebbi F, Sodagari N, Hedayat A. Diagnostic values of ultrasound and the Modified Alvarado Scoring System in acute appendicitis. *International journal of emergency medicine* 2012 Dec;5(1):1-5.
7. Xifara S, Katergianakis V, Vlastarakos P, Skaltsas S, Loulakis I, Bramis I. The role of ultrasound in the diagnosis of acute appendicitis. *Hellenic Journal of Surgery* 2013 Jan;85:35-41.
8. Blomqvist PG, Andersson RE, Granath F, Lambe MP, Ekblom AR. Mortality after appendectomy in Sweden, 1987-1996. *Annals of surgery* 2001 Apr;233(4):455.
9. Nshuti R, Kruger D, Luvhengo TE. Clinical presentation of acute appendicitis in adults at the Chris Hani Baragwanath academic hospital. *International journal of emergency medicine* 2014 Dec;7:1-6.
10. Barlas SU, Günerhan Y, Palanci Y, İşler B, Çağlayan K. Epidemiological and demographic features of appendicitis and influences of several environmental factors. *Turk J Trauma Emerg Surg* 2010;16(1):38-42.
11. Lounis Y, Hugo J, Demarche M, Seghaye MC. Influence of age on clinical presentation, diagnosis delay and outcome in pre-school children with acute appendicitis. *BMC pediatrics* 2020 Dec;20:1-9.
12. Federico C, Paola F, Massimo S, Enrico C, Maria GS, Gioacchino L, Gian LD, Federica G, Matteo T, Fausto C, Luca A. Conservative treatment of acute appendicitis. *Acta Bio Medica: Atenei Parmensis* 2018;89(Suppl 9):119.
13. Zouari M, Jallouli M, Louati H, Kchaou R, Chtourou R, Kotti A, Dhaou MB, Zitouni H, Mhiri R. Predictive value of C-reactive protein, ultrasound and Alvarado score in acute appendicitis: a prospective pediatric cohort. *The American journal of emergency medicine* 2016 Feb 1;34(2):189-92.
14. Stephens PL, Mazzucco JJ. Comparison of ultrasound and the Alvarado score for the diagnosis of acute appendicitis. *Connecticut Medicine* 1999 Mar 1;63(3):137-40.
15. Nautiyal H, Ahmad S, Keshwani NK, Awasthi DN. Combined use of modified Alvarado score and USG in decreasing negative appendectomy rate. *Indian Journal of Surgery* 2010 Feb;72:42-8.