

CASE REPORT

Extramarital Affair Claims Child's Life

***Dalal Deepsekhar¹, Dey Arijit², Biswas Sujash³,
Das Abhishek⁴, Bandyopadhyay Chandan⁵, Banerjee Molly⁶***

Received on March 22/2015; accepted (revised) on April 19/2015; approved by author on May 15/2015

ABSTRACT

In India two out of three children suffer from various types of abuse be it physical, emotional or sexual. Though the reasons can be manifold, mostly the sufferers are unwanted children. The present case is about a two year old female child who was brutally beaten by her mother, upon provocation by the mother's lover and was thrown away in a river bank. Though found alive at the time of recovery, she died in the hospital four days later. Meticulous autopsy examination was corroborative with the said incidence with evidences of multiple injuries all over the body including various fractures of bones. This is a unique case report of brutal physical abuse of a child who paid for her mother's extramarital affair.

Keywords: Abuse, Unwanted children, Brutally, Autopsy

INTRODUCTION

According to World Health Organisation, child abuse or maltreatment constitutes all forms of physical and/or emotional ill-treatment, sexual abuse, neglect or negligent treatment or commercial or other exploitation, resulting in actual or potential harm to the child's health, survival, development or dignity in the context of a relationship of responsibility, trust or power.¹ There are four types of child abuse, i.e., physical abuse, sexual abuse, emotional abuse and neglect. In India, two out of three children suffer from various types of abuse be it physical, emotional or sexual. What we see in print or electronic media truly is the tip of the iceberg. The true prevalence of violence against children is difficult to establish because of not or under-reporting this problem.²

CASE HISTORY

A local fisherman of Jhargram went to the bank of Subarnarekha river in the morning for fishing as a part of his daily routine. Suddenly he saw a baby's head nearby, with the rest of the body from neck remaining buried inside the sand, in a semiconscious state. He also found bits of broken biscuits and other food material around the baby on the surface of the ground. He rushed and recovered the unconscious injured body of a baby girl by digging up the sandy soil with the help of some local people. Later he informed the matter to the local police station. On the same day the girl was admitted in NRS Medical College and Hospital but she was referred to several hospitals several times fearing complications. The baby succumbed due to her injuries four days later in the late night. Next day she was sent for autopsy.

Address for correspondence and reprint:

¹Assistant Professor (**Corresponding Author**)

Forensic Medicine and Toxicology, ICARE Institute of Medical Sciences and Research and Dr. B.C. Roy Hospital, Haldia, WB. **Email:** deepsekhaldal@gmail.com

Mobile: 09433402243

²PGT Forensic Medicine and Toxicology, NRS Medical College; ³Asst Prof. Forensic Medicine and Toxicology, Medical College Kolkata; ⁴Asst Prof. Forensic Medicine and Toxicology, Sikkim Manipal Institute of Medical Sciences, Sikkim; ⁵Asst Prof. Forensic Medicine and Toxicology, Medical College Kolkata; ⁶Demonstrator, Forensic Medicine and Toxicology, NRS Medical College, Kolkata

The story as we could gather from the police was very shocking. The baby's parents, belonged to poor socio economic class. After the birth of the first daughter the father was not very happy only because it was a girl child. They were not at all a happy couple. The father worked far from home on daily wage basis for months together in different sites. Now, after the birth of the second daughter the situation deteriorated drastically. The husband blamed his wife for everything and they fought over small petty issues. In the meantime, a mason shifted into that area when the baby's father was away for his job. Gradually the baby's mother and this mason came closer and they decided to marry. The mason's idea was to get rid off the little child because the elder one was a bit fond of her father and won't make any problem if her mother leaves her. Understanding the situation that the younger one will never leave her mother, the mason and the baby's mother decided to kill her. So, one night just after having dinner, the mother started beating the younger child mercilessly. Next morning in the early hours she took away the unconscious baby to the bank of the Subarnarekha river. She then dug up some sandy soil by the riverside and buried the baby upto neck keeping the head outside in the air. Moreover, she left some food around the head thinking that some scavengers would be attracted to the food and eat up the child at the same time. Now the fisherman happened to see the unconscious half-buried body and informed the police.

AUTOPSY FINDINGS

The body was of a two year old female child who was of normal built, moderate nourishment and brown complexion. Height was 2.5 feet. Rigor mortis was not present and post-mortem staining was appreciable on the dependent parts of the body.

IMPORTANT EXTERNAL INJURIES

1. One round abrasion 1 cm in diameter, 2 inches above the right eyebrow over the temple.
2. One oval abrasion (2.5x1) cm in measurement, 1.7 inches above the left eyebrow over the temple.
3. Bilateral black eyes.

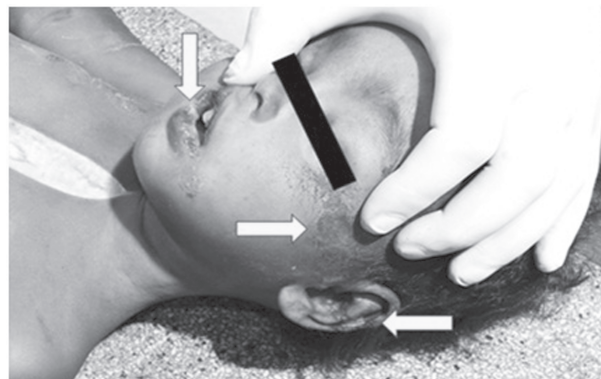


Figure 1 Abrasions on face, ear and injuries on lips

4. One abrasion starting just below the lateral canthus of the left eye extending upto a grossly straight line 2 cm in front of the left tragus measuring (2x1) inches. Another abrasion centrally on external ear over an area of (1x0.5) inch. Severely bruised both lips with areas of scattered abrasion over and inside (**Figure 1**).

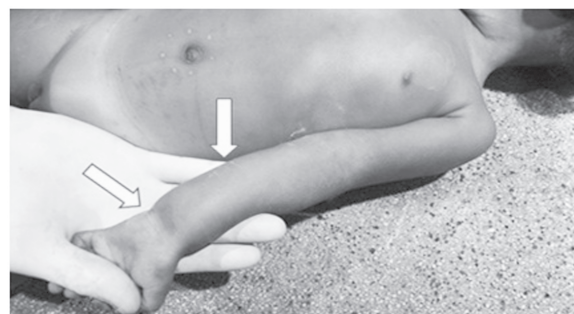


Figure 2 Contusion on left wrist, forearm and elbow crease. Fractures of forearm bones (left) appreciable

5. One bruise over an area of (2x2) inches just in front of left wrist joint. Another bruise around the left elbow joint. Cattered areas of bruise over the mid part of swollen left forearm (**Figure 2**).

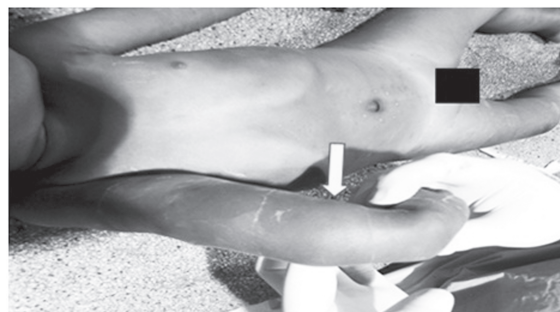


Figure 3 Fractures of forearm bones (right) appreciable

6. Areas of discrete scattered bruises over the swollen right arm and forearm (**Figure 3**).
7. Scratch abrasions 3-5 in number and 4 inches in length on an average starting from the left flanks and ending 1.5 inches left to the midline on the back.

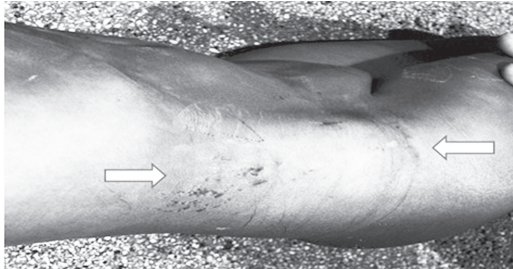


Figure 4 Multiple abrasions in the right flank

8. Scattered graze and scratch abrasions over right flanks measuring (4x3) inches tending to go backward (**Figure 4**).
9. Abrasion of 1 cm diameter over the upper right side of right knee joint.
10. One 0.2 cm puncture wound on the back side of right knee joint.

IMPORTANT INTERNAL INJURIES

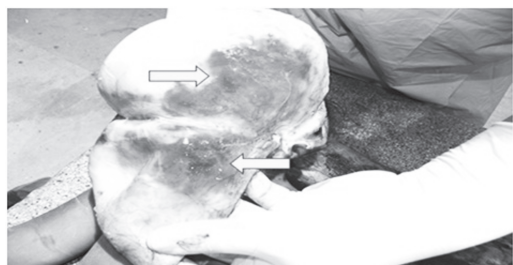


Figure 5 Scalp haematoma

1. One scalp haematoma over the right parietal bone measuring (4x3) inches (**Figure 5**).

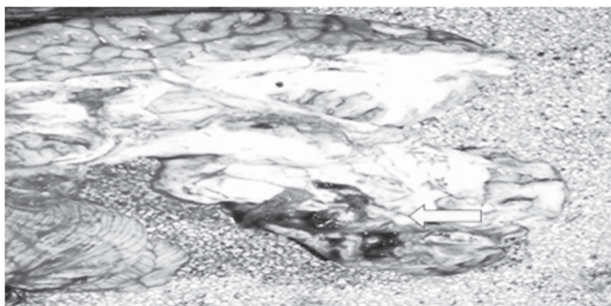


Figure 6 Intracerebral haemorrhage

2. Subdural and subarachnoid haemorrhages over both cerebral haemorrhages with few blood clots.
3. Intracerebral haemorrhage in the right occipital lobe (**Figure 6**).
4. Fracture of the lower end of the left radius.
5. Fracture of the left forearm 2 inches below the elbow crease.
6. Fracture of the right forearm 2.5 inches below the elbow crease.
7. All the viscerae were congested.

DISCUSSION

Although child abuse occurs at all socioeconomic levels, it is highly associated with poverty and psychosocial stress, especially financial stress. Child maltreatment is strongly correlated with less parental education, underemployment, poor housing, welfare reliance and single parenting.³ The World Health Organisation in the year 2000 estimated that about 57000 children died from fatal maltreatment.¹ The death of the baby merely was an unfortunate outcome of extramarital love affair who proved to be an obstacle to the new pair. She also had to die to pinpoint to the large unreported cases of killing of unwanted female child. Here, in this particular case the child proved herself to be unwanted to her father for just being a girl and also a hindrance to the sprouting extramarital affair. The psyche of our society should consider these two things separately while both are interconnected.

The mother who was convicted, confessed that after feeding the girl at night she held the baby's hair and struck her against the wall and the floor, which resulted in intracerebral haemorrhages and abrasions over the face. Head trauma is the leading cause of child abuse fatalities.⁴ As the baby started crying the mother tried to stop her by pressing over the baby's mouth with her hands resulting in the bruised appearance of the lips. She was hit with a stick on the forearms which broke them on both sides. A pointed instrument was inserted into the right knee joint area from the back. Gradually the girl became unconscious and was taken away by the mother to the banks of Subarnarekha river in the early hours where women of that village used to go to defaecate. To ensure the child's death, just after burying her up to the neck level she threw some food around to attract scavengers thinking they might devour the baby as well. Fortunately the baby was recovered but died after hospitalisation. The cause of death was intracranial haemorrhages though there were no fractures of the skull. The most common

cause of death in abused children is intracranial damage, with or without skull fracture.⁵ Paediatric abusive head injury causes death in approximately 30% and permanent neurologic damage in upto 80% of victims.⁶

CONCLUSION

There are various components of child abuse: child, care giver stress, etc. Childhood world over is not homogenous, several childhood co-exist depending on the social status, economic status, physical ability, mental ability and geographical location. Physical abuse of children takes place across cultures, societies, economic and social strata. It is seen largely in homes where frustrations are high; parents have poor parenting skills and have little or no self-control; where there are visible marital problems, substance abuse, domestic violence and so on. Children are physically small, vulnerable and totally dependent on parents. A child is dependent on parents for all his/her needs be it food, shelter, protection, health care, love and care or education. He/she is constantly seeking approbation and positive reinforcement of his/her own value from the parent/caregiver. Thus, constant physical abuse can be extremely demoralizing for the child, no matter what the provocation. Often the child is the easiest target for the parents to vent their frustration on. It is important to understand that the cycle of abuse is self-perpetrating. A child who has faced severe forms of abuse during childhood is likely to become an abuser in later years.⁷

There can be four types of child abuse: physical abuse, sexual abuse, emotional abuse and neglect.¹ Physical abuse is physical aggression directed at a child by an adult.⁶ Child sexual abuse (child molestation) is the involvement of dependent, developmentally immature children and adolescents in sexual activities. They do not truly understand and to which they are unable to give informed consent or which violate social taboos or family rules.⁸ Emotional abuse includes degradation, destruction of personal belongings, excessive criticism, humiliation, inappropriate or excessive demands, name-calling, ridicule, torture, with holding communication.⁶

Only few cases of child abuse and/or death come to the surface. To conclude, suspected cases of child abuse should be well documented and reported to the appropriate public agency which should assess the situation and help to protect the child.⁹ Here is a poster which shows that we can call 1098 if we want to help a needy child (Figure 7).¹⁰

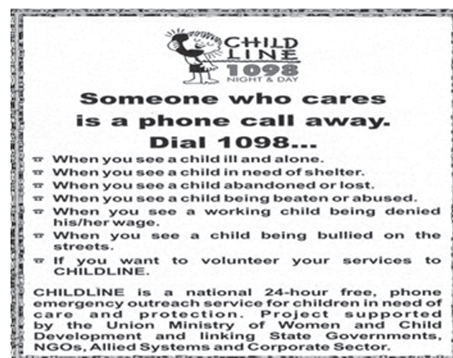

Figure 7 Child Line Poster

Contribution of Authors: We declare that this work was done by authors named in this article and all liabilities pertaining to claims relating to the content of this article will be borne by the authors.

Conflict Of Interest: None.

Declaration: This article has not been submitted anywhere else for publication.

REFERENCES

1. Krug EG, Dahlberg LL, Mercy JA, Zwi AB, Lozano R. World report on violence and health, World Health Organization Geneva 2002; p. 59-60.
2. Mahanta P. Modern Textbook of Forensic Medicine and Toxicology. 1st ed. New Delhi: Jaypee brothers Medical Publishers (P) Ltd; 2014. p. 165.
3. Sadock BJ, Sadock VA. Kaplan & Sadock's synopsis of psychiatry: behavioral sciences/clinical psychiatry: 10th ed. Wolters Kluwer Lippincott Williams and Wilkins. p. 1339.
4. Kellogg ND, MD and the Committee on Child Abuse and Neglect. Pediatrics: June 1, 2007;119(6):1232.
5. Saukko P, Knight B. Knight's Forensic Pathology, 3rd ed. London: Arnold; 2004. p. 469.
6. Agarwal A. Textbook of Forensic Medicine and Toxicology. Abichal publishing company; 1st ed. 2014. p. 483-485.
7. Kacker L. Study on child abuse: India. Ministry of women and child development, Government of India, 2007. p. 49.
8. Reddy KSN, The essentials of forensic medicine and toxicology. 33rd ed. New Delhi: Jaypee brothers Medical Publishers (P) Ltd; 2014. p. 425.
9. Dubowitz H, Bennett S. Physical abuse and neglect of children. Lancet. 2007 Jun 2;369 (9576):1891-9.
10. Available from: URL:<http://www.childlineindia.org.in>.