

CASE ARTICLE

Crime Scene Visit in Determining the Manner of Death in an Unusual Case of Hanging

Debbarma Antara¹, Chakrabarty Suman Kumar²

Received on June 27, 2015; Accepted (revised) on September 27, 2015

ABSTRACT

Determining the manner of death in an unusual case of hanging is a dilemma for all members of the judiciary system, especially forensic medicine doctor and forensic scientists. This case report depicts a very unusual case of hanging of a young adult male in his own house with his hands tied in front. This created a huge hue and cry among the common public for their age-old belief on homicidal hanging. However, a meticulous crime scene investigation and a postmortem examination helped in shedding light on the manner as unusual case of suicidal hanging rather than homicidal hanging.

Keywords: Unusual case of hanging, suicidal hanging

INTRODUCTION

Differentiating between a suicidal hanging and homicidal hanging suddenly becomes difficult due to the unusual ways adopted by the victim and the complexity thus posed. Thus investigating these unusual cases of suicide provides considerable challenge to the authority not only because of the complexities of the case but also because of public pressure and their misbeliefs.¹ A joint venture of meticulous crime scene investigation followed by equally meticulous autopsy along with circumstantial evidence and data collection definitely helps in reaching a verdict.

CASE REPORT

A 21 year old young adult male was found in a hanging condition by a nylon rope, from the wooden beam of the ceiling of his own room which was bolted from inside, at about 03:00 pm of last June. In a very unusual gesture, a leather belt in the front side tied both wrists of the deceased. Left wrist was tied in multiple knots and right wrist was just held loosely in a loop. As the deceased was reported to be inside his room for unusual long hours, the neighbours informed the police who forced entry into the room after breaking the door. By the time the public started creating commotion on the unusual gesture of the dead and straight way concluded it to be a homicidal hanging. A thorough crime scene investigation was done and the body was sent for autopsy.

CRIME SCENE INVESTIGATION

The room was mud walled with CGI sheet roofing. The room had two doors which were locked from inside with no other point of entry. The police forced the main entrance

Address for correspondence and reprint:

¹ (Corresponding author) Assistant Professor
Department of Forensic Medicine
Malabar Medical College Hospital and Research Centre,
Modakkallur, Calicut

Email: antaradebbarma@gmail.com

Mobile: 08794517591

²Deputy Director (Chemistry division), SFSL, Narsingarh,
Tripura

door open in presence of several witnesses. The deceased was found hanging by a plastic rope from the wooden beam under the ceiling. The body was above the bed and the feet was touching the bed, one wooden tool inversely placed on the bed. The distance between suspension point to bed was 8 ft 2 inches, suspension point to knot at the neck was 2ft 2 inches (approx.), height of wooden tool was 1ft 5 inches, length of body was 5ft 9 inches (after elongation), distance between bed to floor was 1ft 6 inches. The findings are suggestive that the deceased easily achieved the suspension point. The knot was positioned centrally at back. There was protrusion of tongue with reddish stains, dribbling of saliva from mouth at the opposite end of the knot, nasal discharge. The trouser was found wet likely due to discharge of urine (**Figure 1**).

The hand of the deceased was observed to be loosely knotted at the front with black coloured waist belt. The gaps between the two hands were 2.6 inches. There were some cobwebs adhered on dorsum of both the hands, supposedly, from the ceiling/beam while fixing knots, etc., (**Figure 2**).



Figure 1 Crime scene picture

AUTOPSY FINDINGS

The deceased was a young adult male 21 years of age, average built and height. On external examination, wearing apparels were one brown coloured vest with red coloured shoulder straps and a khaki green coloured full pant. A

leather belt on the anterior aspect of the body tied both his wrists. The right wrist was tied in a single loop and his left wrist was tied in a double loop without any knot which can be separated easily (**Figure 2**). There were no injuries present underneath the knot (**Figure 3**). The ligature mark, brownish in colour, grooved, non-continuous, and hard like parchment and having a maximum width of 03 cm was present obliquely and incompletely around the neck. The mark was situated 2.8cm below the tip of right mastoid process, 05 cm below the chin, 10 cm above the suprasternal notch and 04 cm below the tip of left mastoid process. On dissection of the neck, the underlying subcutaneous tissue was found pale and glistening with no extravasation of blood and with intact cartilages (**Figure 4**).

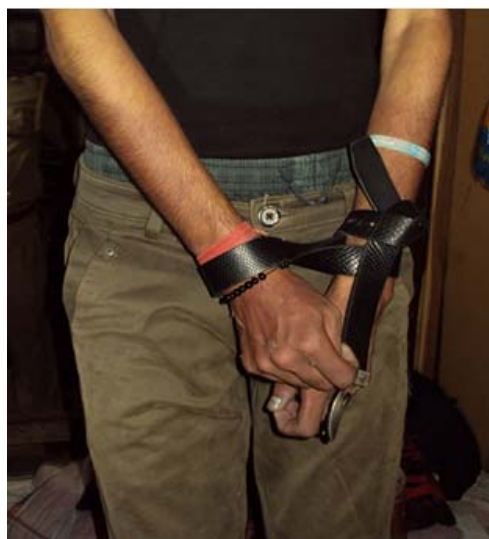

Figure 2 Loosely tied wrists with leather belt and cobwebs sticking on the palm

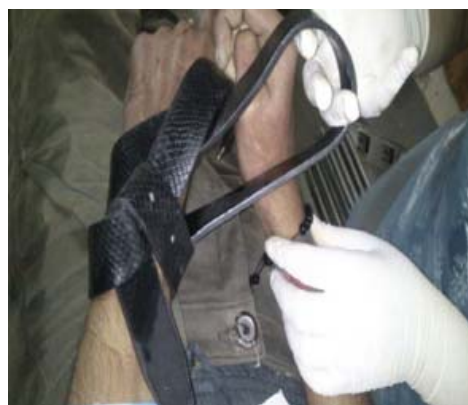

Figure 3 Showing wrists tied loosely in simple loop with no underlying injuries

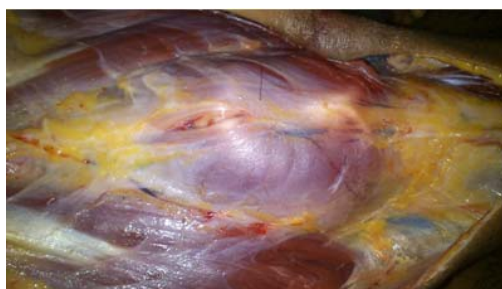


Figure 4 Picture of underlying neck structure in autopsy showing no extravasations

DISCUSSION

From the crime scene investigation report and autopsy report, the case was concluded to be an unusual case of a typical partial hanging which was suicidal in nature and the investigating officer was directed accordingly. Gorniak et al in 2005 reported three such cases of suicide by hanging with bound hands in Franklin County, Ohio within a period of 4 months where initially police termed the case to be of “suspicious in nature” because of the unusual presentation.² F A Benomran in his study on “Masking and bondage in suicidal hanging” described a man of 35 years found in hanging condition in an isolated place with hands loosely tied and vest wrapped around his head and upper part of neck. Though initially it was suspected to be a case of autoerotic asphyxia, however after thorough crime scene investigation and autopsy it was concluded to be suicidal in nature.³ U.K.D.A. Goonetilleke, in his study also described of two such cases of unusual suicide, where in the first case the deceased’s left hand tied to the left thigh with the head and face covered by a heavy winter coat. In the second case the deceased’s hands were tied behind his back.⁴ Marsh et al and Takac S in their similar case reports depicted unusual suicidal hanging with hands tied at the back and mouth gagged.^{5, 6} Demirci et al in his study conducted at Konya province, Turkey from 2002 to 2006, reported 17 such similar cases of unusual suicidal hanging. According to the author, these are all precautions and preventive measures observed by the victim to avoid abandoning the act.⁷ Venneman and Emson reported a case of accidental autoerotic asphyxia.^{8, 9} However, in our present case report no such circumstantial evidence of auto erotic acts was reported. Cliver Trevor Cooke, Gerard Andrew Cadden and Karin Ann Margolius in their study conducted in Western Australia, however, reported a very high incidence suicidal hanging in males of age group 15 to 35 years.¹⁰

CONCLUSION

Unusual cases of suicide are dilemma to the judiciary system and maximum time considered death under “suspicious nature”. However these are nothing but precautions and preventions taken by the victim to avoid abandoning the act. But the possibility of autoerotic asphyxia and homicidal hanging also has to be borne in mind and accordingly has to be ruled out. A meticulous crime scene investigation and autopsy, together with inquiry data helps in solving such dilemma.

Acknowledgement: The authors are thankful to the Director, SFSL and Head of Department of Forensic Medicine, AGMC, Tripura for their kind support and encouragement in taking up the study.

Consent: Informed consent was taken from the parent.

REFERENCES

1. Arun M, Paimar V, Kumar G N P, Ménages R G. Unusual methods of suicide: Complexities in investigation. *Med Sci Law* 2010 Jul;50(3):149-53.
2. Gorniak, Jan M, Sudimack JR, Stanforth JR, Lewis, Bradley JL. Hanging deaths with bound hands: what is the manner? *Am J Forensic Med Path* 2007 Sept;28(3):232-4.
3. Benomran F A, Masood S E, Hassan A I, Mohammad A. Masking and bondage in suicidal hanging. *Med Sci Law* 2007 Apr;47(2):177-80.
4. Goonetilleke U K D A. Two unusual cases of suicide by hanging. *Forensic Sci Int* 1984 Dec;26(4):247-53.
5. Marsh, Thomas O, Burkhardt, Richard P M D, Swinehart, James W M D. Self Inflicted hanging with bound wrists and a gag. *Am J Forensic Med Path* 1982 Dec;3(4):294-373.
6. Takac S, Budakov B, Stojanovic P. A suicide by hanging suspected to be a homicide. *Med Pregl* 1997;50(7-8):315-8.
7. Demirci, Serafettin, Dogan, Hakan K, Erkol, Zerrin, Deniz, Idris. Precautions taken to avoid abandoning the act of hanging and reducing pain in suicidal hanging cases. *Am J Forensic Med Path* 2009 Mar;30(1):32-5.
8. Venneman B, Pollack S. Death by hanging while watching violent pornographic videos on the internet-suicide or accidental autoerotic death? *Int J Legal Med* 2006 Mar;120(2):110-4.
9. Emson H E. Accidental hanging in autoeroticism: An unusual case occurring outdoors. *Am J Forensic Med Path* 1983 Dec;4(4):337-40.
10. Cooke CT, Cadden G A, Margolius K A. Death by hanging in Western Australia. *Path* 1995;27(3):268-72.