

ORIGINAL PAPER

Cadaveric study on the branching pattern of profunda femoris artery and its circumflex branches

Momin D Ambath¹, Singh Th Dineshor², Sharma Amitav³, Das Ch Gautam⁴, Bhuyan Biraj⁴

Received on July 15, 2016; editorial approval on October 15, 2016

ABSTRACT

Introduction: Variation of the profunda femoris artery and its branches are not uncommon. Since profunda femoris artery (PFA) is the chief artery supplying the thigh; knowledge of its variations is very important for any surgical procedure of the thigh. **Materials and method:** 24 lower limbs were dissected and the following points were noted. The relation of profunda femoris artery at its origin from the femoral artery was noted. The distance of the site of the origin of the profunda femoris from the midpoint of the inguinal ligament was measured. Also the sites of origin of the lateral circumflex femoral artery (LCFA) and medial circumflex femoral artery (MCFA) were noted and the distance of site of origin of each of them from the origin of profunda femoris artery were also measured. **Results:** Majority of profunda femoris artery arise from a posterolateral aspect of femoral artery at a distance of 21-41mm away from the midpoint of inguinal ligament. Whereas majority of lateral circumflex femoral artery arise from the lateral aspect of profunda femoris artery at a distance of 11-40mm away from the origin of profunda femoris. Majority medial circumflex femoral artery arises from the medial aspect of femoral artery at a distance of 11-30mm away from origin of the profunda femoris artery. **Conclusion:** Knowledge of variations in the origin of these arteries is very important for surgeons while performing surgical procedures in the thigh to avoid complications.

Keywords: Medial and lateral circumflex artery, inguinal ligament, variations

INTRODUCTION

The profunda femoris artery is the main artery supply of the thigh arising from the lateral side of the femoral artery about 3-4 cm distal to the inguinal ligament. Lateral and medial circumflex femoral arteries, arise from the profunda femoris artery from the lateral and medial side respectively.¹ The profunda femoris artery

is frequently incorporated in the vascular reconstructive surgery.² The knowledge of variations in height of origin of profunda femoris artery and its branches is of great significance for preventing flap necrosis, particularly tensor fascia latae, when used in plastic and reconstructive surgery.³ Gautier et al⁴ stated that the precise knowledge of anatomy of medial circumflex femoral artery is essential while performing both trochanteric and intertrochanteric osteotomies and is also helpful to avoid iatrogenic vascular necrosis of the head of the femur in reconstructive surgery of hip and fixation of acetabular fractures through the posterior approach.

MATERIAL AND METHODS

24 lower limbs from 12 cadavers (7 male and 5 female) were dissected in the department of Anatomy RIMS Manipur in collaboration with the department of Anatomy NEIGRIHMS, Shillong. Femoral artery and its branches were identified and traced by using conventional method of dissection. The relation of profunda femoris artery (PFA) at its origin to the femoral artery was noted. The distance of the site of the origin of the profunda femoris from the midpoint of the inguinal ligament was measured. Also the sites of origin of the lateral circumflex femoral artery

Address for correspondence:

¹SRD (Corresponding Author)

Department of Anatomy, NEIGRIHMS, Shillong, 793018
Mobile: +919402508583

Email: drambath2000@gmail.com

²Singh Th. Dineshor, Sr. Medical officer,
Dist. Hospital Bishnupur, Imphal

³Sharma Amitav, Associate Professor, NEIGRIHMS, Shillong

⁴Das C. Gautam, SRD, Department of Anatomy,
NEIGRIHMS, Shillong

⁵Bhuyan B. Curator of Museum,
Department of Anatomy, NEIGRIHMS

(LCFA) and medial circumflex femoral artery (MCFA) were noted and the distance of site of origin of each of them from the origin of profunda femoris artery were measured.

OBSERVATION AND RESULT

Distance of origin of profunda femoris from the midpoint of inguinal ligament: Out of 24 femoral artery, 66.6% of profunda femoris artery arise at a distance of 21-41mm away from the inguinal ligament, whereas 39.1% arise at a distance of 41-60mm and only 4.1% in the present study it arise at a distance of 10-20mm away from inguinal ligament (Table 1).

Table 1 Distance of origin of Profunda Femoris from the midpoint of inguinal ligament

Range (in mm)	Right	Left	Total	% age
10-20	1	-	1	4.1
21-30	3	5	8	33.3
31-40	4	4	8	33.3
41-50	3	1	4	16.6
51-60	1	2	3	12.5

Site of origin of profunda femoris from femoral artery: 50% of the profunda femoris artery arises from the posterolateral part (Figure 1, 2, 3), 29.1% from posterior whereas 20.8% arise from the lateral aspect (Table 2).

Table 2 Site of origin of profunda femoris from femoral artery

Site	Right	Left	total	% age
Posterolateral	7	5	12	50
Lateral	2	3	5	20.8
Posterior	3	4	7	29.1

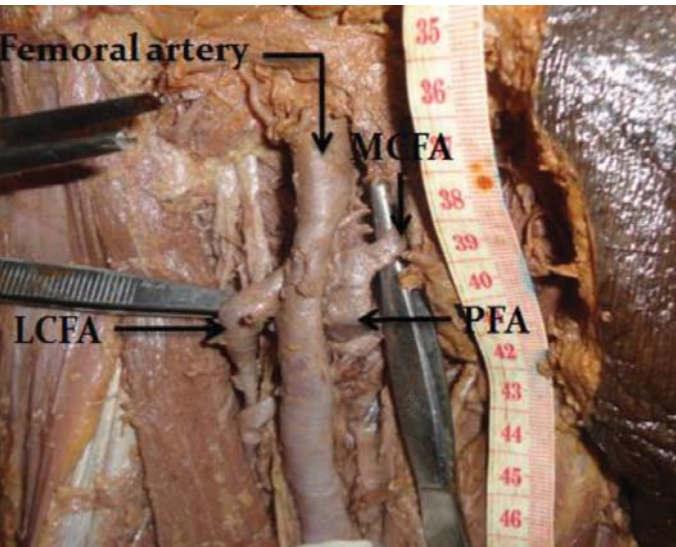


Figure 1 Normal branching pattern showing both medial and lateral circumflex femoral artery originating from profunda femoris artery

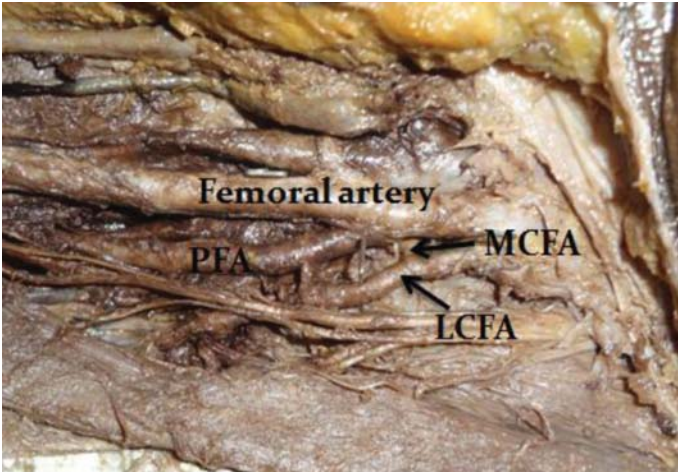


Figure 2 Showing common trunk of origin for both the circumflex artery which itself arise directly from femoral artery

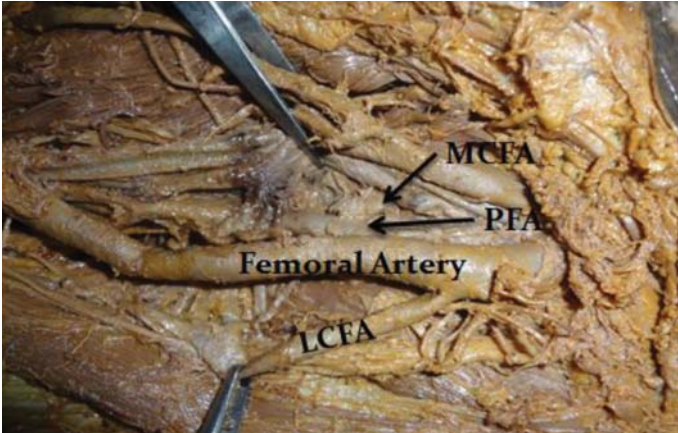


Figure 3 Showing Lateral circumflex femoral artery (LCFA) originating directly from the lateral aspect of femoral artery

Table 3 Distance of origin of lateral circumflex femoral artery from origin of the Profunda Femoris artery

Range (in mm)	Right	Left	Total	% age
0-10	2	1	3	12.5
11-20	3	4	7	29.1
21-30	3	1	4	16.6
31-40	3	2	5	20.8

Origin of the lateral circumflex femoral artery (Table 4): 79.2% arise from the lateral aspect of profunda femoris artery and 20.8% arise directly from the femoral artery proximal to the origin of profunda femoris artery (Figure 1, 2, 3).

Table 4 Origin of the lateral circumflex femoral artery

Origin (From)	Right	Left	Total	% age
PFA on lateral aspect	11	8	19	79.1
Femoral artery superior to the origin of PFA	1	4	5	20.8

Distance of origin of medial circumflex femoral artery from origin of the profunda femoris artery: 70.7% of it arises at a distance of 11-30mm away from origin of the profunda femoris artery, 20.8% at a distance of 0-10mm, and only 4.1% at a distance between 31-40mm (**Table 5**).

Table 5 Distance of origin of medial circumflex femoral artery from origin of the Profunda Femoris artery

Range(in mm)	Right	Left	Total	%age
0-10	2	3	5	20.8
11-20	4	6	10	41.6
21-30	5	2	7	29.1
31-40	1	-	1	4.1

Origin of medial circumflex femoral artery (Table 6): 95.6% arise from medial aspect whereas 4.1% arise from the lateral circumflex femoral artery (**Figure 2**) on its medial aspect (as common trunk).

Table 6 Origin of medial circumflex femoral artery

Origin (From)	Right	Left	Total	%age
PFA on medial aspect	12	11	23	95.6
LCFA from medial aspect	-	1	1	4.1

DISCUSSION

The profunda femoris artery (deep femoral artery) is a large branch that arises laterally from the femoral artery about 3.5 cm distal to the inguinal ligament.¹ Brijesh RA, Sujatha K, T Fatima⁵ stated that the average distance of PFA from inguinal ligament is 30-40 mm. The term "high origin" of profunda femoris artery is used when it originates from the femoral artery at a distance of 0-10mm away from the inguinal ligament. The advantage of high origin (0-10mm) of PFA is that it can be used for catheterization and for further investigation of any arterial system of the body.⁶ In the present study we have found that majority of it arise at a distance of 21-41mm away from the inguinal ligament and we did not encounter even a single case of high origin. So the finding of the present study is more or less similar with the findings of above mentioned authors.

The most common site of origin of PFA is from posterolateral aspect of femoral artery.^{1,7} But according to Siriporn et al,⁸ and Samarawickrama et al,⁹ the most common site of origin of PFA is from posterior aspect, i.e. 44.64% & 46% respectively. In our study we found that majority of it arise from the posterolateral aspect of femoral artery whereas only 29.1% of it takes origin from posterior aspect.

Umez M et al,¹⁰ stated that 77.3% of the LCFA arise from the PFA and 22.7% arise from the femoral artery. Fukuda H et al,¹¹ also found that majority of LCFA arise from PFA. Baptish M,¹² reported its origin from femoral artery. Whereas Tanyeli E,¹³ reported the origin of LCFA from femoral artery inferior to the origin of PFA. In our study we have found that 79.2% of LCFA arise from the lateral aspect of profunda femoris artery and only 20.8% of it takes origin directly from the femoral artery proximal to the origin of profunda femoris artery

In most cases LCFA arise from the PFA at a distance in between 21-30mm.⁶ In our study majority of LCFA i.e. 70.7% arise at a

distance of 11-30mm away from origin of the profunda femoris artery, whereas 20.8% of it arise at a distance of 0-10mm, and only 4.1% of LCFA arise at a distance 31-40mm away from the origin of PFA.

Daksha Dexit,⁶ reported that the distance of origin of MCFA from the origin of PFA was mostly 0-10 mm. In our study it is mostly arise at a distance of 11-30 mm away from origin of the profunda femoris artery. Present study shows that MCFA mostly originates from the medial aspect of the PFA in both sides. This is comparable to the finding of Daksha dexit,⁶ Lipshutz BB.¹⁴ Clarke.¹⁵ Evans CA et al,¹⁶ reported that MCFA & LCFA arising by a common trunk from the femoral artery. In present study we found that only 4.1% of MCFA arise from the lateral circumflex femoral artery on its medial aspect as common trunk which itself arise from the femoral artery.

CONCLUSION

Variations in the origin of profunda femoris artery and its circumflex branches are very commonly encountered. Knowledge of variations in the origin of these arteries is very important for surgeons while performing surgical procedures in the thigh to avoid complications.

REFERENCES

1. Standing S. Pelvic girdle, gluteal region and hip joint, profunda femoris artery. In: Grey's Anatomy, the anatomical basis of clinical practice. 40th ed. Spain: Churchill Livingstone Elsevier; 2008. p. 1379-80.
2. Siddharth P, Smith NL, Mason RA, Giron F. Variational anatomy of the deep femoral artery. *Anat Rec* 1985;212(2):206-209.
3. Vuksanovic BA, stefanivic N, pavlovic S, Duraskovic R, Randelovic J. Analysis of deep femoral artery origin variances on fetal material. *Factauniversitatis: medicine and Biology* 2007;112-116.
4. Gautier E, Gang K, Krugel N, Gill T, Ganz R. Anatomy of the medial femoral circumflex artery and its surgical implications. *J Bone Joint Surg Br* 2000;82(5):679-683.
5. Brijesh RA, Sujatha K, T. Fatima. Morphological study of origin of profunda femoris artery in human cadavers. *Int J Anat Res* 2015;3(3):1376-80
6. Dixit DP, Metha LA, Kothari ML. Variations in the course of profunda femoris. *J Anat Soc India* 2001;50(1):6-7.
7. Hollinshead: Buttock, hip joint, and thigh, profunda femoris artery. In: *Anatomy for surgeons: Vol.3. The back and limbs*. 2nd ed. New York: Happer & Row; 1969. p. 725-30.
8. Siriporn T, Rungruang T, Voraphattropas C. The origin of profunda femoris artery in Thais. *Siriraj Med J* 2012;64:34-36.
9. Samarawickrama MB, Nanayakkara BG, Wimalagunaratna KWR, NishantaDG, WalwageUB. Branching pattern of femoral artery at the femoral triangle: A cadaver study. *Galle Medical journal* 2009;14:1.
10. Uzel M, Tanyeli E, Yildirim. Anatomical study of the origin of lateral circumflex femoral artery in Turkish population. *Folia Morphol (Warsz)* 2008;67(4):226-230.
11. Fukuda H, Ashida M, Ishii R, Abe S, Ibukuro K. Anatomical variants of the lateral femoral circumflex artery: an angiographic study. *Surg Radiol Anat* 2005;27(3):269-264.
12. Baptist M, Sultana F, Hussain T. Anatomical variation of the origin of profunda femoris artery, its branches and diameter of the femoral artery. *Professional Med J* 2007;14(3):523-527.
13. Tanyeli E, Yildirim M, Uzel M, Ural F. Deep femoral artery with 4 variations- a case report. *Surg Radiol Anat* 2006;28(2):211-213.
14. Lipchut BB. Study on the blood vascular tree, 1, A complete study of the femoral artery. *Anat Rec* 1916;361-370.
15. Clarke SM, Colborn GL. The medial femoral circumflex artery; its clinical anatomy and nomenclature. *Clin Anat* 1993;6(2):94-105.
16. Evans CA, Smith KS, Jarolim L. Observation of two uncommon variations of proximal branches of femoral artery. *Faseb J* 2007;776,11.