

Neglected posterior hip dislocation: its management in 18 years old female and review of the literature

Abstract

Neglected traumatic dislocations of the hip is one of disabling condition in lower extremity which are seldom found in adults And it is not an uncommon condition seen in developing countries. Its treatment is fraught with great difficulties and controversies. Here we present 18 years old female who presented to our hospital with 7 years old posterior hip dislocation sustained following fall from bicycle . She had gone through multiple treatments for her dislocated hip without any success. After arrival to our hospital, patient managed by Girdlestone osteotomy and skeletal traction followed by total hip replacement (THR) with uncemented acetabular cup and cemented femoral stem. Her Harris hip score improved from 48 (preoperative) to 81 (postoperative). On follow-up she had a good range of movement of the hip with no pain, deformity and limb length discrepancy. Girdlestone osteotomy and skeletal traction followed by total hip replacement (THR) provides promising results in neglected hip dislocation.

Introduction

Neglected traumatic dislocations of the hip are rare in adults. However, in developing countries, unreduced traumatic dislocations are not uncommon. They are usually the result of a motor vehicle accident, often combined with multiple trauma including head injury, fracture of the ipsilateral femur or bilateral injuries, which may detract attention from the dislocation^[1]. Neglected hip dislocations occur in situations when the patient does not or cannot seek adequate medical care. As such, chronic dislocations may be observed in patients with a high pain tolerance, patients with decreased cognitive ability to recognize or verbalize their pain and patients with additional injuries that are more obvious or life-threatening^[2].

In developing countries, patients usually attend hospital many days after trauma, having often received alternate therapy before. Treatment of neglected dislocation of the hip becomes more difficult to manage as time progresses because of the soft tissues contractures, adhesions, fibrofatty tissue filling of the acetabulum, and presence of myositis ossificans.^[3]

Reduction of neglected dislocation of hip is not only difficult but results in avascular necrosis and arthritis. Total hip replacement (THR) is recommended for hip dislocations with duration more than 3 months ^[2].

A complete understanding of the factors that play a role in the etiology of instability of hip and a clear knowledge of treatment options are mandatory for the surgeon tackling this injury. Girdlestone osteotomy and skeletal traction followed by total hip replacement (THR) is a viable option for neglected dislocation hip.

Case report

18 years old female sustained a fall from bicycle, resulting in an injury of her left hip, causing pain and an inability to weight bear. She saw a local doctor, who diagnosed a dislocation of her hip and attempted a reduction, which failed, as the hip remained painful und unstable. Six months after the injury, the patient consulted an orthopedic surgeon, who adviced to undergo an open reduction of the hip, but patient abandoned treatment .

We saw this patient 7 years after the initial injury complaining of hip pain. She was walking with an antalgic gait and had a decreased range of motion of her hip. The limb was in fixed adduction and internal rotation. She had a leg length discrepancy due to 5 cm shortening of left lower extremity. Her hip movements were restricted and painful. Radiographs confirmed a persistent dislocation of the hip, with a false acetabulum in the left supra-acetabular region(figure 1).

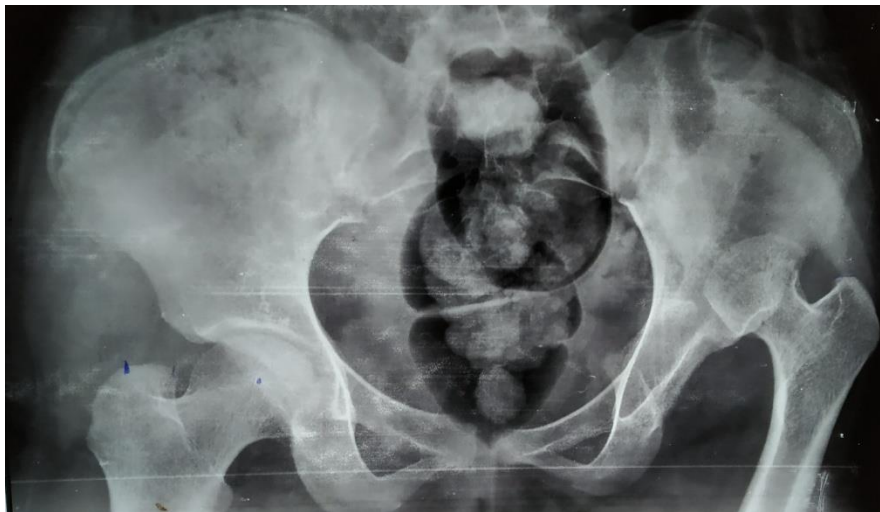

Figure 1: Pre-operative x-ray of the pelvis, showing neglected left posterior hip dislocation.

Initially open reduction was planned for this patient with 2 weeks prior skeletal traction. During surgery, we encountered soft tissues contractures, adhesions, fibrofatty tissue filling of the acetabulum, and enlargement of femur head. This anatomical distortions made it almost impossible open reduction of hip. we decided to clear acetabulum of fibrous tissues and did Girdlestone osteotomy and soft tissue release (figure 2). Post operative skeletal traction with increasing weight was given for approx. 2 months and serial weekly X rays were done. Traction was ceased when the greater trochanter was drawn at the level of articular surface of the acetabulum (figure 3). Then THR was done with uncemented acetabular cup and cemented femoral stem with proximal femoral encirclage (figure 4). The leg lengths were equalized, and the postoperative recovery was uneventful. Roentgenograms showed satisfactory position and fitting of the prosthesis.

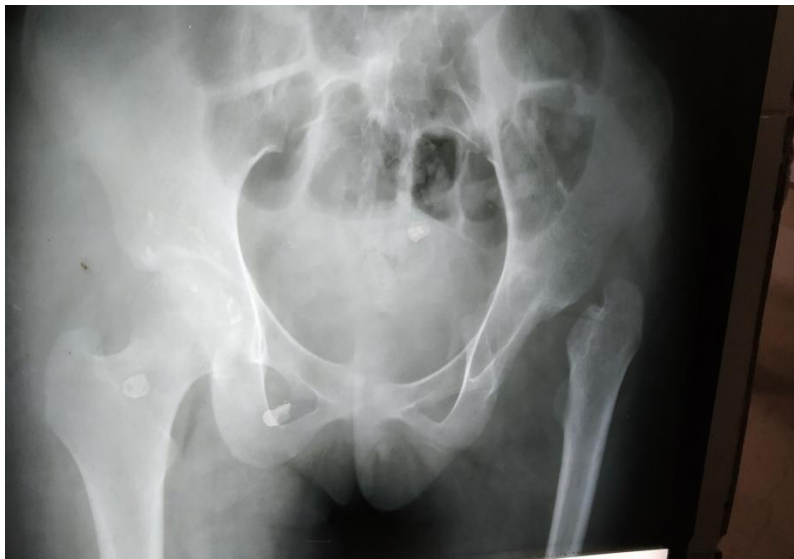

Figure 2: The x-ray of the pelvis after the first operation, showing post Girdlestone osteotomy and skeletal traction.

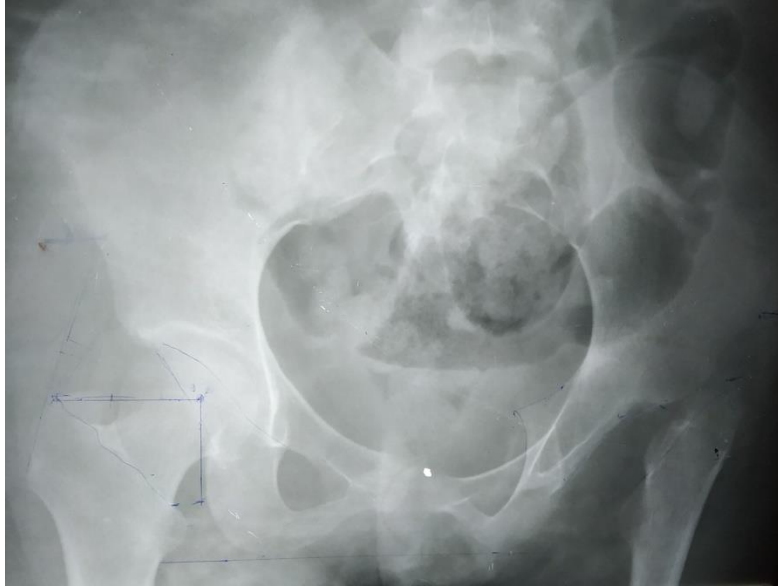


Figure 3: The x-ray of the pelvis after the greater trochanter was drawn at the level of articular surface of the acetabulum.

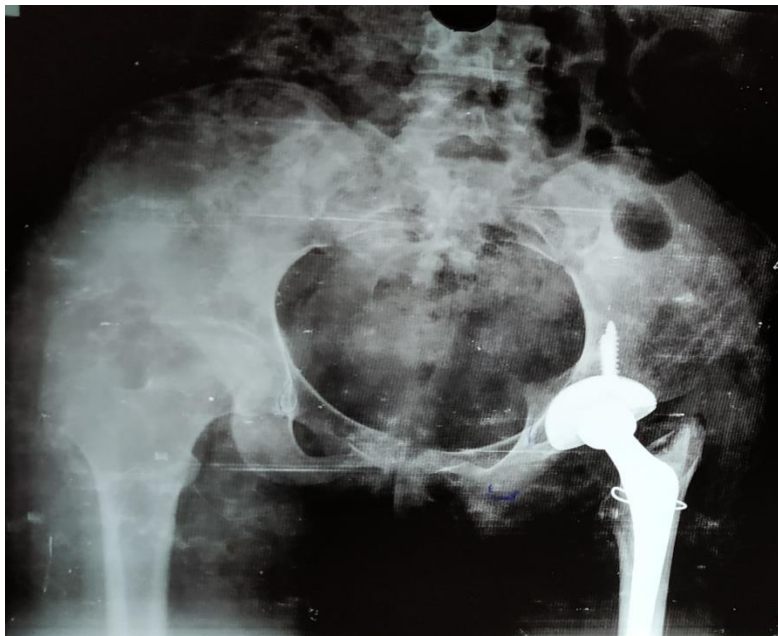


Figure 4: Post-operative pelvic X-Ray of the patient after total hip replacement.

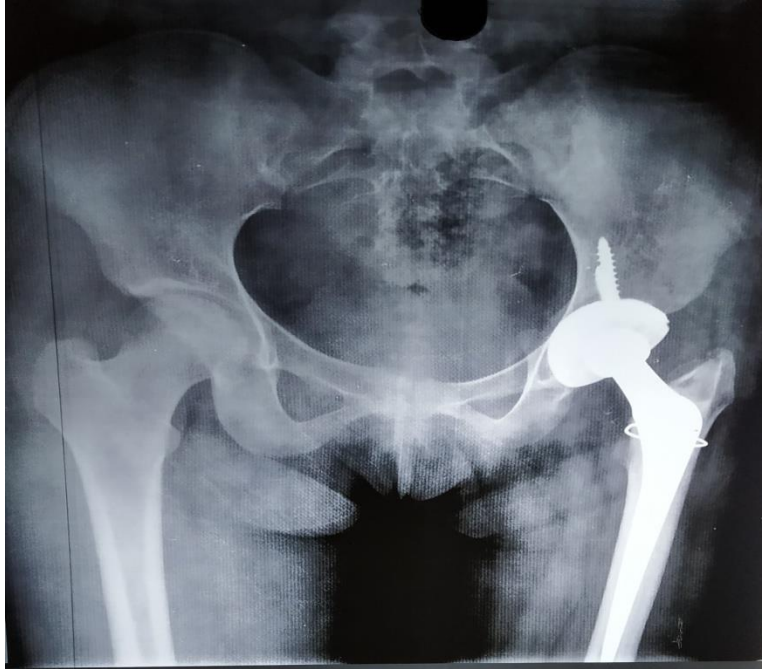

Figure 5: 3 months Post operative follow up pelvic X-Ray of the patient after total hip replacement.

Her physiotherapy was started soon postoperatively, and she was discharged on the fourteenth postoperative day. Her functional status improved on every successive follow-up visit, and the HHS score improved from 48 (preoperatively) to 87 (postoperatively). She had no pain, a mild residual Trendelenburg gait due to her abductor insufficiency and excellent function.

Discussion

The ongoing discussion of the best treatment option for the management of neglected dislocation hip continues and remains controversial. Various studies reported different methods for operative treatment of neglected fracture–dislocations including the use of a sub-trochanteric osteotomy, the Girdlestone procedure, hip arthrodesis, hemiarthroplasty and total hip replacement ^[4]. All these procedures have their merits and give different outcomes. The results can be further altered by avascular necrosis of the femoral head which occurs in more than 50% of these cases. Garrett et al. ^[2] has recommended total hip arthroplasty for hips with posterior dislocations classified as type IV (fracture of the acetabular rim

and floor) or type V (fracture of the femoral head with or without other fractures) with dislocations for more than 3 months.

Pai recommended reduction under anaesthesia for patients where a dislocation had occurred three days to three weeks previously.^[5]

Banskota et al. ^[4] in their study of eight cases with neglected posterior dislocation on hip reported good results in three cases treating the hip with an open reduction. They achieved a mean Harris hip score of 89 (range 84–96). Leg lengths were within 2 cm in seven of the eight cases, and one patient had a discrepancy greater than 2 cm.

Verma et al. ^[6] in his study of 14 cases neglected dislocation ranging from 14 days to 1 year duration performed open reduction and reported excellent results in four cases, but also had poor outcomes in five cases.

In a study conducted by Berend et al. ^[7] using a constrained THR, ten percent were primary hip replacements in patients with an abductor dysfunction secondary to trauma or neuromuscular disease. They reported promising results, which would indicate that constrained THR to be a viable alternate option with abductor dysfunction with a high dislocation risk.

In a study conducted by Paavilainen et al. 100 cementless total hip replacements in 52 severely dysplastic and 48 totally dislocated hips, with some new technical solutions to the problems involved. In hips with tight flexor and abductor muscles or with deformities of the proximal femur, various osteotomies were performed. Final results were generally good limited correction of limb length discrepancy may be achieved with THR. ^[8]

Patel et al, presented a case of 30 years-old male patient with neglected hip dislocation. The patient complained pain in the left hip for 2 years with fixed deformity of the hip, with history of fall from a tree 15 years ago. The radiographs showed an obturator dislocation of the hip with obvious pseudo-acetabulum around the dislocated femoral head. Uncemented total hip arthroplasty was performed and after 2 years follow up, the patient was able to walk unaided without pain.^[9]

Ilyas et al, treated 15 patients with chronic unreduced hip fracture-dislocations result from motor vehicle injury at King Faisal Specialist Hospital & Research

Center. All underwent 1-stage total hip arthroplasty with bone grafting and then monitored for 36-96 months range. Although there were 2 dislocations, 1 transient peroneal nerve palsy, and 1 superficial infection, but generally all patients had significantly decreased pain, increased function, and increased range-of-motion scores using the Merle d'Aubigné scoring system.^[10]

Kumar et al, reported a 31 years old female patient with neglected hip dislocation. The initial injury was 2 years before the patient's presentation to hospital and had gone through many multiple treatments for her disease without any improvement. The patient was treated by constrained total hip replacement, resulting in improvement of Harris Hip Score from 48 to 81. On follow up, the patient showed improved range of motion of hip joint without pain.^[11]

CONCLUSION

Our case of 7 years old neglected dislocation of the hip treated by Girdlestone osteotomy and skeletal traction followed by total hip replacement (THR) with uncemented acetabular cup and cemented femoral stem total hip replacement which improves the patient's functional status successfully. Despite gaining 5–6 cm of limb length, sciatic nerve was unaffected which is indirectly favouring Eggli et al. ^[12] who found no correlation between the amount of lengthening and sciatic nerve palsy in a large study on THR.

We have not found any other case report with a 7-year-old neglected dislocated hip with contractures of the stabilizing muscles and pseudoarthrosis, as in our case, having achieved a satisfactory conclusion.

REFERENCES

1. Hougaard K, Thomsen PB. Traumatic posterior fracture–dislocation of the hip with fracture of the femoral head or neck, or both. *J Bone Joint Surg Am.* 1988;70:233–239. doi: 10.2106/00004623-198870020-00011. [PubMed] [CrossRef] [Google Scholar]
2. Garrett JC, Epstein HC, Harris WH, Harvey JP, Jr, Nickel VL. Treatment of unreduced traumatic posterior dislocations of the hip. *J Bone Joint Surg Am.* 1979;61:2–6. doi: 10.2106/00004623-197961010-00002. [PubMed] [CrossRef] [Google Scholar]
3. Pugalenth PV, Ramanathan S, Thanappan N, Sagar MV. A rare case of neglected unreduced posterior dislocation of hip managed with total hip arthroplasty-a case report. *J Evolut Med Dent Scie.* 2017 Mar 20;6(23):1953-7.
4. Banskota AK, Spiegel DA, Shrestha S, Shrestha OP, Rajbhandary T. Open reduction for neglected traumatic hip dislocation in children and adolescents. *J Pediatr Orthop.* 2007;27(2):187–191. doi:10.1097/BPO.0b013e31802c547e. [PubMed] [CrossRef] [Google Scholar]
5. Pai VS, Kumar B. Management of unreduced traumatic posterior dislocation of the hip: heavy traction and abduction method. *Injury.* 1990;21:225–227. doi: 10.1016/0020-1383(90)90008-I. [PubMed] [CrossRef] [Google Scholar]
6. Verma BP. Management of old unreduced traumatic dislocation of hip. *Indian J Orthop.* 1975;9(2):69–80. [Google Scholar]
7. Berend KR, Lombardi AV, Jr, Mallory TH, Adams JB, Russell JH, Groseth KL. The longterm outcome of 755 consecutive constrained acetabular components in total hip arthroplasty examining the successes and failures. *J Arthroplasty.* 2005;20(7 Suppl 3):93–102. doi: 10.1016/j.arth.2005.06.001. [PubMed] [CrossRef] [Google Scholar]
8. Paavilainen T, Hoikka V, Solonen KA. Cementless total replacement for severely dysplastic or dislocated hips. *J Bone Joint Surg.* 1990;72(2):205–11.

9. Patel S, Thimmegowda RB, John R, Kumar TS, Arjun RH. Total hip arthroplasty in neglected, obturator type, hip dislocation in a young adult—an unusual case and literature review. *J Arthrosc Joint Surg*. 2017 Jan 1;4(1):50-3.
10. Ilyas I, Rabbani SA. Total hip arthroplasty in chronic unreduced hip fracture-dislocation. *J Arthropl*. 2009 Sep 1;24(6):903-8.
11. Kumar S, Dahuja A, Narula MS, Garg S, Kaur R. Neglected hip dislocation: an unusual presentation, its management and review of the literature. *Strat Trauma Limb Reconst*. 2017 Nov 1;12(3):189-92.
12. Eggli S, Hankemayer S, Muller ME. Sciatic nerve palsy after limb lengthening in THR. *J Bone Joint Surg Br*. 1999;81(5):843–845. doi: 10.1302/0301-620X.81B5.9610. [PubMed] [CrossRef] [Google Scholar]