

CASE REPORT

A Treatment Refractory Case of Taenia Saginata in a Tertiary Care Hospital

Dina Raja¹, Chimanjita Phukan², Naba Kumar Hazarika³

Received on March 05/2015; accepted (revised) on April 19/2015; approved by author on May 11/2015

ABSTRACT

We report a case of an 11 year-old, muslim boy in whom a 1.4-meter long worm was expelled in his faeces. He gives a history of frequent expulsion of the worm through his nostrils and mouth too, which is an unusual presentation. He was advised treatment with tab Nicloside and tab Albendazole and given supportive treatment for other minor complaints like vomiting, loss of appetite, fatigue and weight loss. In Assam, Taenia Solium more commonly causes taeniasis. Documented cases attributable to Taenia Saginata in this part of the country are very few. This case has been reported as a treatment failure as he still continues to expel worm in his faeces even after been admitted in various hospital for his problem. Taeniasis is a preventable disease and measures should be taken to bring down its incidence.

Keywords: Beef tapeworm, Proglottids, Taeniasis

INTRODUCTION

Taeniasis is endemic in Southeast Asia. Two species from the genus Taenia are common parasites of humans; the pork tapeworm or *T. solium* and the beef tape worm or *T. saginata*. Recent studies suggest that the Taenia found in Asia is a subspecies of *T. saginata* and it has been renamed as *T. saginata asiatica*.¹ Infection is acquired by taking improperly cooked beef or pork. Most cases of taeniasis are asymptomatic and usually complain of passage of Proglottids with stools. However, others present with pruritus ani (77%), nausea (46%), abdominal pain (43%), dizziness (42%), increased appetite (30%), and other mild gastrointestinal symptoms.² We report the case of an 11 year old Mohammedan boy coming with complaints of passage of worms in stool and through nostrils off and on for the last 5 months. On investigation, he was found to be suffering from Taenia saginata infection. He was advised Nicloside and Albendazole and given supportive treatment for other minor complaints like vomiting, loss of appetite, fatigue and weight loss. In Assam, Taeniasis is more commonly caused by Taenia solium. Documented cases attributable to Taenia saginata in this part of the country are very few.

CASE HISTORY

An 11-year-old boy came to the department of Microbiology with a worm measuring approximately 1.4 meters long that was passed in the stool (**Figure 1**).

Address for correspondence and reprint:

¹Associate Professor (**Corresponding Author**)

Email: dinaraja@hotmail.com

Mobile: 09864039629

²Associate Professor, ³Professor and HOD, Dept. of Microbiology, Gauhati Medical College and Hospital, Guwahati



Figure 1 *Taenia saginata* (naked eye)

A muslim boy from the Darrang district of Assam presented to the paediatric outpatient department with history of passage of 1½ to 2 metre long worm in his stool 5 months back. This was followed by appearance of a 2 metre long worm from the nostrils after 2-3 days. Thereafter, there was frequent passage of worms in his stool for which he received treatment at the local PHC with antihelmenthic and liver support. A month later as he was still passing worms in his stool he sought treatment at Mangaldoi CHC. He was prescribed Albendazole suspension and Lactitol Monohydrate suspension daily at bed time for 3 weeks and on not being cured, he was referred to Gauhati Medical College Hospital. He was admitted in the pediatrics ward and on investigation he gave a history of loss of appetite and nausea for the same duration and consumption of beef regularly. Physical examination of the patient was normal, except mild tenderness in the epigastric region, tachycardia was noted, with normal blood pressure. Laboratory investigations revealed hemoglobin of 9g/dl, a leucocyte count of 12300/μl and eosinophil count of 13%. X-ray and ultrasonography of the abdomen was normal. He was treated with Albendazole and discharged after a week. However, after a brief respite from his symptoms there was appearance of worms in his stool again for which he came back to GMCH and was admitted for a second time and advised treatment with niclosamide 500 mg and Albendazole 400 mg tablets daily for 4 weeks. But inspite of being treated, he still complained of passage of worms in his stool.

During his hospital stay he passed another long worm in the stool and came to our lab with it. Naked eye examination could ascertain it as a tapeworm with

definite segments. On measuring its length it was found to be around 1.4 meters, with a quadrate head and flattened segmented body. On enquiring further regarding his living conditions and food habits, it was found that they belonged to an economically poor section and lived in an unhygienic condition. His diet included beef consumption both attributable to *Taenia* infection. There were also indications from the patient's version that the beef was consumed under cooked.

We advised him to give another stool sample for examination which was examined by direct saline wet mount (**Figure 2**) and concentration methods. Saline wet mount revealed broken segments of the adult worm and few eggs, which were bile stained (**Figure 3**), and spherical measuring about 40 μm in diameter. The outer shell was not appreciated clearly, inner embryophore was brown, thick walled and radially striated with an oncosphere and hooklets. In the concentration method, the stool sample was concentrated by formalin in acetone and wet mount was prepared from the sediment for examination. The recovery of eggs by concentration method was much better and the yield was much higher.

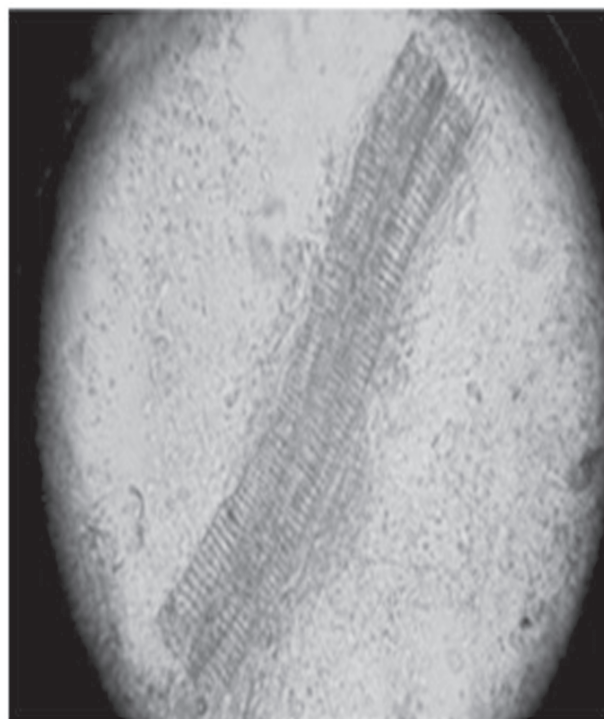


Figure 2 Saline wet mounts reveals Proglottids

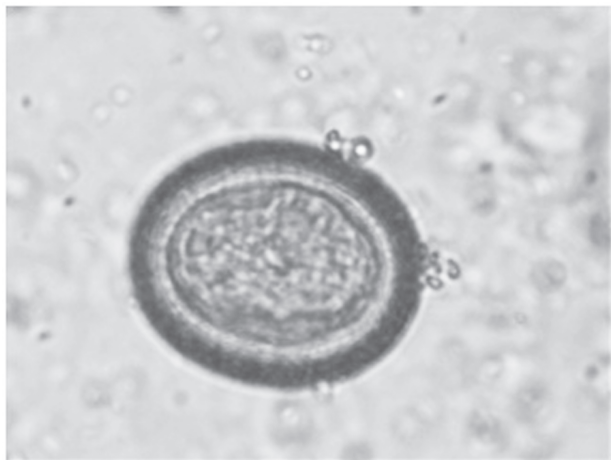


Figure 3 Bile stained egg of *Taenia saginata*

DISCUSSION

T. Saginata is the largest of species in the genus *Taenia*. An adult worm is normally 4 to 10 m in length, but can become very long; specimens over 22 m long are reported.³ The disease is relatively common in Africa, some parts of Eastern Europe, the Philippines, and Latin America.³ This parasite is found where beef is consumed, even in countries such as the United States, with strict federal sanitation policies. In the US, the incidence of infection is low, but 25% of cattle sold are still infected.⁴ The total global infection is estimated to be between 40 and 60 million.⁵ It is most prevalent in Sub-Saharan and the Middle East.⁶

The basic diagnosis is done from a stool sample where faces are examined to find the eggs of the parasite. The eggs of the Taeniidae family look alike, so it is only possible to identify the eggs to the family level and not to the species level. Therefore, looking at the scolex or the gravid proglottids can help in identifying it as *Taenia saginata*.⁴ Proglottids sometimes trickle down the thighs of infected humans and are visible with unaided eye, so can aid in identification. Observation of scolex helps to distinguish the three different species of *T. saginata*, *T. solium* and *T. asiatica*. When the uterus is injected with India ink, its branches become visible. Counting the uterine branches enables some identification (*T. saginata* uteri have 12 or more branches on each side, while other species such as *T. solium* only have five to 10).³

Differentiation of the species of *Taenia*, such as *T. solium* and *T. asiatica*, is notoriously difficult because of their

close morphological resemblance, and their eggs are more or less identical. Identification often requires histological observation of the uterine branches and PCR detection of ribosomal 5.8S gene.⁷ The uteri of *T. saginata* stem out from the center to form 12 to 20 branches, but in contrast to its closely related *Taenia* species, the branches are much less in number and comparatively thicker; in addition, the ovaries are bilobed and testes are twice as many.⁸

Eosinophilia and elevated IgE levels are chief hematological findings. Also Ziehl- Neelsen stain can be used to differentiate between mature *T. saginata* and *T. solium*, in most cases *T. saginata* will stain while *T. solium* will not, but the method is not strictly reliable.⁹

Taeniasis is easily treated with praziquantel (5–10 mg/kg, single-administration) or niclosamide (adults and children over 6 years: 2g, single-administration after a light breakfast, followed after 2 hours by a laxative; children aged 2–6 years: 1g; children under 2 years: 500 mg).¹⁰ Praziquantel opens membrane calcium channels of the worm causing its paralysis, aiding the body in expelling the parasite through peristalsis. Albendazole is also highly effective for treatment in man.

CONCLUSION

Taeniasis is prevalent in many states of India and occurs commonly among the beef consuming communities. In Assam taeniasis cases are most commonly caused by *Taenia solium* with neurocysticercosis being very common. Documented cases attributable to *Taenia saginata* in this part of the country are very few. Cases refractory to treatment has not being reported. Taeniasis is a preventable disease and measures should be undertaken to bring down its incidence. Methods like maintenance of hygiene in cattle raising areas, proper disposal of human faces, meat inspection programs and proper preparation of food before consumption have an important role in controlling the infection and these measures should be strictly implemented.

REFERENCE

1. Fan PC, Lin CY, Chen CC, Chung WC. Morphological description of *Taenia saginata asiatica* (Cyclophyllidae: Taeniidae) from man in Asia. J Helminthol 1995;69(4):299-303.

2. Fan PC, Chung WC, Lin CY, Chan CH. Clinical manifestations of taeniasis in Taiwan aborigines J Helminthol 1992;66(2):118-123.
3. Somers, Kenneth D, Morse, Stephen A. Lange Microbiology and Infectious Diseases Flash Cards (2nd ed.). New York: Lange Medical Books/ McGraw-Hill; 2010. p. 184-186.
4. Roberts, Larry S, Janovy J, Gerald D. Schmidt and Larry S. Roberts' Foundations of Parasitology. 8th ed.). Boston: McGraw-Hill Higher Education; 2009. p. 348-351.
5. Eckert J. Helminthol. In Kayser FH, Bienz KA, Eckert J, Zinkernagel RM. Medical Microbiology. Stuttgart: Thieme; 2005. p. 560-562.
6. Ortega, Ynes R. Foodborne parasites. New York: Springer; 2006. p. 207-210.
7. Gonzalez LM, Montero E, Harrison LJ, Parkhouse RM, Garate T. Differential diagnosis of *Taenia saginata* and *Taenia solium* infection by PCR. J Clin Microbiol 2000;38(2):737-744.
8. Zarlenga DS. The differentiation of a newly described Asian taeniid from *Taenia saginata* using enzymatically amplified non-transcribed ribosomal DNA repeat sequences. Southeast Asian J Trop Med Public Health 1991;22:251-255.
9. Jimenez JA, Rodriguez S, Moyano LM, Castillo Y, García HH. Differentiating *Taenia* eggs found in human stools- Does ZiehlNeelsen staining help? Trop Med Int Health, 2010;15(9):1077-1081.
10. Taeniasis / cysticercosis. WHO Fact sheet N°376 2013; [cited 2015 February 7]: Available from: URL:<http://www.who.int/mediacentre/factsheets/fs376/en/>

Academic Excellence of Founder Life Member of IJHRMLP



Dr. Soumeek Chowdhuri receiving certificate for best paper at Chennai Forensic Medicon (Scottish travel award) 2015