

CASE REPORT

Child abduction homicide by adolescent perpetrators: a rare case report

Sengupta Deepmalya¹, Biswas Sujash²

Received on 21st May 2020; editorial approval on 30th June 2020

ABSTRACT

Cases of child abduction and homicide though rare but are often overwhelming due to the public and media attention. While numerous studies on child abuse and neglect have been conducted throughout the country and worldwide, research on child abduction and homicide remains scant. We report such a case of a child who was abducted and eventually smothered to death by a couple of adolescent perpetrators. We also intend to better understand these types of child abduction homicides and to analyze strategies that will help to revamp the expertise into such criminal investigations.

Keywords: Child abduction; homicide, smothering; juvenile hate crimes; adolescents.

INTRODUCTION

Often children are found missing for a short period and they reappear on their own without any testament of foul play. Nevertheless, children do get missing against their prerogative. A majority of them do undergo traumatic and stressful experiences but are returned home alive without any serious physical anguish. A very small group of these abducted children are gravely victimized, either they are sexually molested or killed.

The list of children who are abducted and killed each year by someone who is a stranger is relatively small, compared to the number of missing children or other types of child murder. Worldwide there is approximately one child abduction murder for every 10,000 reported missing children.¹ In India, child abduction murder has a very low frequency of all murders committed. And even fewer children are killed by asphyxia, i.e., either by strangulation or smothering.

As the victims of child abduction murders are unique among murder victims, so too are their killers. About 1/10th of them are juvenile. But cases of juvenile hate crimes have become more prevalent over the past 25 years. This may be due to a drastic cultural and societal change which has been marked by a lack of a parent in the home providing guidance and/or poor peer selection.² Regardless, child abduction murders where the perpetrators are adolescents themselves are extremely few. And this makes our case unique and unexampled.

CASE HISTORY

A 4-year-old male child (**Figure 1**) was found lying dead near a bamboo forest at around 7 AM. The local people of the village informed the police personnel who identified the body of the subject. Incidentally, a missing report was lodged in the same Police Station on the previous evening with the child being missing from 4 PM. The post-mortem examination was arranged. On further investigation, two adolescent boys of 12 and 13 years respectively were nabbed by the police,

Address for Correspondence:

¹Senior Resident (**Corresponding author**)

Department of Forensic Medicine

Cooch Behar Government Medical College & Hospital

Mobile: +919933127831

Email: deepmalyasen@gmail.com

Home address: 83A, Naba Nagar, Jadavpur, Kolkata-700032, India

²Associate Professor of Forensic Medicine

Rampurhat Government Medical College & Hospital

Mobile: +918017650885

Email: drsujashnrs@gmail.com

Cite this article as: Deepmalya Sengupta, Sujash Biswas. Child abduction homicide by adolescent perpetrators: a rare case report. *Int J Health Res Medico Leg Prae* 2020 July;6(2):60-62. DOI 10.31741/ijhrmlp.v6.i2.2020.13

and they admitted to having killed the child. The boys confessed that the child was playing with a costly mobile phone near his own house in the late hours of the evening. The two adolescent boys then lured him to a secluded place and took his phone from him. When the child started crying and shouting, the boys smothered him to death and disposed of the body in a gunny bag and kept it in the bamboo forest in the dark of the night.

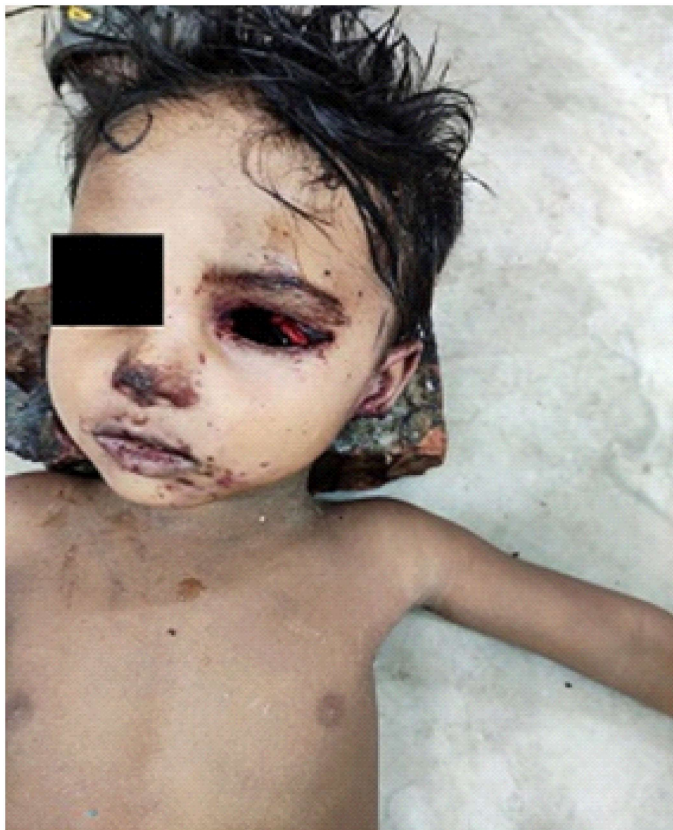

Figure 1 The deceased child

AUTOPSY FINDINGS

The post-mortem examination revealed the subject was of medium built and was moderately nourished. Rigor mortis was present all over the body. On external examination, evidence of bluish discoloration was found over the nail beds, tips of fingers and lower lip. The tip of the nose was found to be flattened. Post mortem gnawing was found over both right and left lobules of the ear with the absence of both sided lower one-third of the ear lobules. Post-mortem gnawing over the left eye with partial evisceration with extrusion of intraocular contents was noted. Linear abrasions were found both on the right and left cheek. Abrasions were found placed over the left side of the chin adjoining the left labial commissure. One subcutaneous tissue deep bruise was found measuring 0.8" x 0.5" over the left side of the chin just below the left labial commissure. Bruises were also found diffused over the tip of the nose and inner aspects of the upper and lower lips with evidence of fracture of the nasal septum with extravasations of blood in and around. The abrasions were fresh and non-scabbed and the bruises were reddish. On

dissection, all the internal organs were seen to be congested. Multiple petechial hemorrhagic spots were found on the serous membranes in the thorax, lungs (**Figure 2**) and the pericardium. Forensic science laboratory gave a negative report for poisoning. Opinion as to the cause of death was given as death was due to effects of asphyxia resulting from smothering - antemortem in nature and homicidal in manner. It was further corroborated with the circumstantial shreds of evidence.

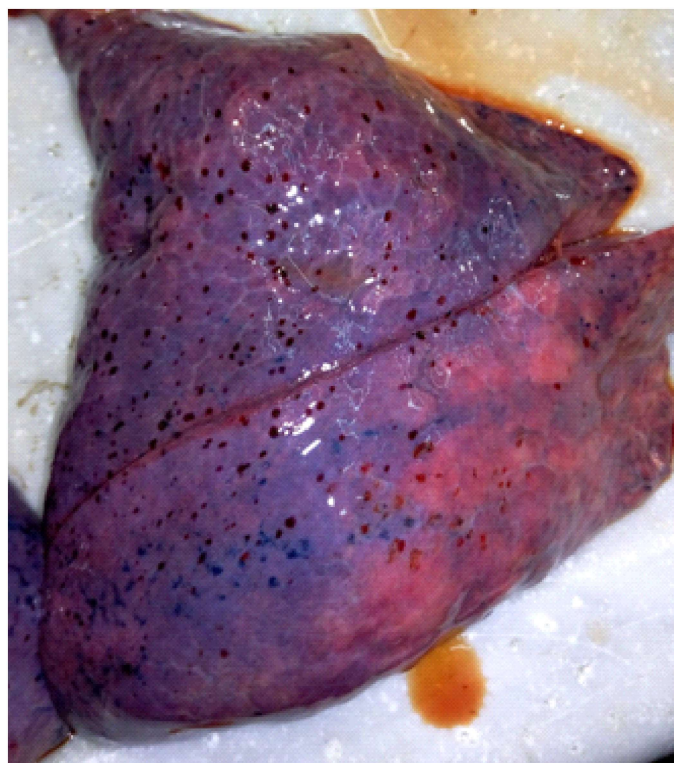


Figure 2 Petechiae on Lungs

DISCUSSION

Child abduction homicides are rare incidents and coupled with their complexity and emotion-laden nature and with the massive media attention, they are extremely difficult to investigate. Investigating officers should always earnestly deal with all reports of a missing child. They need to understand that children are vulnerable in a psychological sense. They are immature and innocent and hence are easily deceived by the offenders. A quick assessment of the nature of the case is to be made with all details surrounding the age of the child, history and circumstances in which the child was missing and then a thorough search to find the body as early as possible. And then to conclude requires a complete and meticulous autopsy and correlating the critical findings at autopsy with the exhaustive crime scene analysis and police interrogations and shreds of evidence. The pivotal aspect in the investigation of a child unexpectedly found dead coupled with suspicious findings, is to establish the accurate manner and cause of death and for a matter of fact all such cases should be considered a potential homicide until proven otherwise.

Smothering refers to a form of asphyxial death from mechanical occlusion of the mouth and the nose (external respiratory orifices), either by hands or by some foreign substances.³ Homicidal smothering is possible when the victim is incapacitated from drink or drugs, debilitated, suffering from ill health, aged or a child as in our case.⁴ But homicidal smothering of a child by adolescent perpetrators is sporadic and unique.

Prevention of juvenile hate crime requires an understanding of the hate crime perpetrator. Adolescence is a time of exploration and experimentation of the surrounding world as the individual strives to develop a sense of self. Hence, the goal should be to address the risk factors and to select the most appropriate form of treatment to minimize them. And as a society, it's upon us to look for the risk factors and warning signs in these adolescents who instigate hate crimes or commits murders. Most often than not, they have a history of conflict with parents and lack of parental affection and support, poor school performance, conduct or aggression problems, impulse-control problems, exposure to television violence or feeling of betrayal and underlying hurt.^{5,6,7} It is recommended that increasing self-esteem, establishing a close bond with the primary caregiver, and enhancing an individual's social and emotional skills along with psychological counselling will go a long way in reducing these rare events of adolescent homicides.⁸

CONCLUSION

Researches on child abduction and homicide are scant and when done suffer from geographical limitations. Further well-designed and large scales studies are needed to be carried out throughout the country to have a better understanding of the cases and have a statistical correlation of the socio-demographic characters and risk factors of children who are abducted and then killed. It would also provide an insight into the psychopathology of the offenders focusing on their psychiatric states and family backgrounds and help in

formulating a plan for investigation of child abduction homicides and their prevention by rapid action and proper investigation.

Conflict of interest: None declared.

Contribution of authors: We declare that this work was done by the author(s) named in this article and all liabilities about claims relating to the content of this article will be borne by the authors. Both the authors conceived and designed the study.

REFERENCES

1. Hanfland KA, Keppel RD, Weis JG. Case Management for missing children homicide investigation. Washington, DC: Homicide Investigation and Tracking System, Attorney General of Washington; 1997.
2. Steinberg A, Brooks J, Remtulla T. Youth hate crimes: identification, prevention, and intervention. *Am J Psychiatry* 2003;160(5):979–989.
3. Reddy KSN, Murty OP. The essentials of forensic medicine and toxicology. 33rd ed. India: Jaypee Brothers Medical Publishers; 2014. p. 360-61.
4. Knight B, Saukko P. Knight's forensic pathology. 3rd ed. London: Edward Arnold; 2004.
5. Beck AT. Prisoners of hate: the cognitive basis of anger, hostility, and violence. New York: HarperCollins; 1999.
6. Cheng TL, Wright JL, Fields CB, Brenner CB, O'Donnell RA, Schwarz D, et al. Violent injuries among adolescents: declining morbidity and mortality in an urban population. *Ann Emerg Med* 2001;37(3):292–300.
7. Shumaker DM, Prinz RJ. Children who murder: a review. *Clin Child Fam Psychol Rev* 2000;3(2):97–115.
8. Douglas K, Bell CC. Youth homicide prevention. *Psychiatr Clin North Am.* 2011;34(1):205–16.